

Original Research Article

<https://doi.org/10.20546/ijcmas.2020.902.266>

Effect of *Lactobacillus sporogenes* Probiotic Bacteria on the Intestinal Histopathology of Indian Magur (*C. batrachus*) Inoculated with Pathogenic Bacteria, *Micrococcus* sp.

Tejpal Dahiya*, Ravikant and Gajender Singh

Chaudhary Charan Singh Haryana Agricultural University, Hisar- 125004 (Haryana) India

*Corresponding author

A B S T R A C T

Keywords

Lactobacillus sporogenes,
Micrococcus sp.,
Probiotics,
histology and
intestine

Article Info

Accepted:
18 January 2020
Available Online:
10 February 2020

Histological slides of the intestine or bowl of Indian magur (*C. batrachus*) was studied under compound microscope to observe the effects of probiotics *Lactobacillus sporogenes* against oxytetracycline resistant pathogenic bacteria *Micrococcus* sp. inoculated on the histology of intestine or bowel; by preparing slides of the small intestinal tissue over a period of eight weeks. The results of histological studies under T1, T2, T3 and T4 treatments showed normal inner lining of intestine of catfishes under normal condition (T1) showed no degeneration and desquamation while the intestinal epithelium of *Micrococcus* sp inoculated catfishes (T2) was very severely degenerated and desquamated in comparison T1 and was correlated with severe enteritis may be due to enhanced counts of mononuclear cells and showed less number of villi than T3 and T4 while the catfishes inoculated with the probiotic *L. sporogenes* (T4) showed more number of villi which indicated the increased absorptive intestinal surface areas. In T4 treated group, increases in intestinal folds were observed with slight mononuclear cell infiltration indicating presence of normal intestinal micro flora.

Introduction

The massive use of antibiotics for the control of diseases in catfishes led to antibiotic resistance in disease causing bacteria and necessitated the need of alternative disease control measures. Recently, probiotics are being used as alternative disease control measures in aquaculture and have been used by people for millennia since the time humans consume fermented milk products lead to normal digestive, endocrine and immunological functions of the bowel by inhibiting pathogenic microorganisms; hence

used to treat variety of gastrointestinal and systemic disorders. Probiotics transiently colonize the bowel and, to treat an acute disorder and regularly consumed to maintain benefit. Use of microbial probiotics to promote health maintenance and disease prevention is now widely accepted. Traditional probiotic dairy strains such as lactic acid bacteria are considered as major sources due to their long history of safe use in foods. However, with a broad range of applications, several probiotic strains now are being investigated and proposed for an alternative medication. In the present

investigation probiotics are used to maintain good intestinal environment in catfish (*Clarius batrachus*) against pathogenic bacterium *Micrococcus* sp.

Materials and Methods

In the present investigation, histology of the intestine was studied under compound microscope to know the effects of probiotics on the intestinal cells by preparing slides of the small intestinal tissue. The slides were prepared by fixing in Bouin's fluid and then material was embedded in paraffin wax and thin sections were cut by a microtome. The Mayer's hematoxylin and eosin stains were used as these eliminates the necessity for differentiation and blurring of the sections and considered a progressive stain; produce a stained section with clearly defined nuclei with completely colorless background. The staining procedure was followed as suggested by Pluske, Hampson, & Williams, (1997), mounted in DPX and viewed under microscope and photographs were taken for study. The effects of *Lactobacillus sporogenes* probiotics bacterium on bowel were observed against oxytetracycline resistant pathogenic bacteria *Micrococcus* sp. and results were compared with control in triplicates with the following treatments: T1 (control) consisted of 250µl of physiological buffer saline (PBS); T2 consisted of only

Micrococcus sp. in 250 µl bacterial suspension in PBS with 5×10^{11} colony forming units (cfu) per ml of bacteria; T3 consisted both pathogenic *Micrococcus* sp. and probiotic *L. sporogenes* (0.1 gm) dissolved in PBS; along with 250 µl of pathogenic bacteria suspension with 5×10^{11} cfu per ml of bacteria while T4 contained only *Lactobacillus sporogenes* (0.1 gm) dissolved in PBS, with 5×10^{11} cfu per ml of bacteria. In the all treatments the bacteria were injected into the intraperitoneal cavity of each catfish in triplicates.

Results and Discussion

The results of histological studies of Indian magur (*C. batrachus*) under T1, T2, T3 and T4 treatments over a period of eight weeks showed normal inner lining of intestine of catfishes under normal condition (T1) showed no degeneration and desquamation (Figure 1) while the intestinal epithelium of *Micrococcus* sp inoculated catfishes (T2) was very severely degenerated and desquamated in comparison T1 and was correlated with severe enteritis due to enhanced counts of mononuclear cells and showed less number of villi (Figure 2) than T3 (figure 3) and T4 while the catfishes inoculated with the probiotic *L. sporogenes* (T4) showed more number of villi which indicated the increased absorptive intestinal surface areas (Figure 4).

Fig.1 Histology of intestine of catfish showing intact intestinal epithelium, villus and lumen of intestine without degeneration and desquamation in control treatment (T1) at 100X magnification

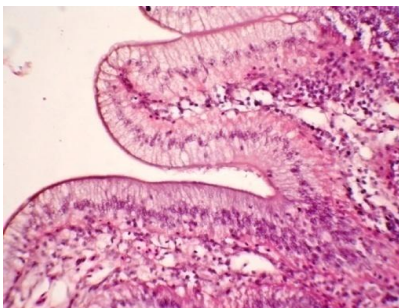


Fig.2 Histology of intestine in *Micrococcus* sp. treated catfish showing very severely degenerated and desquamated villi with less number (T2) at 100X magnification

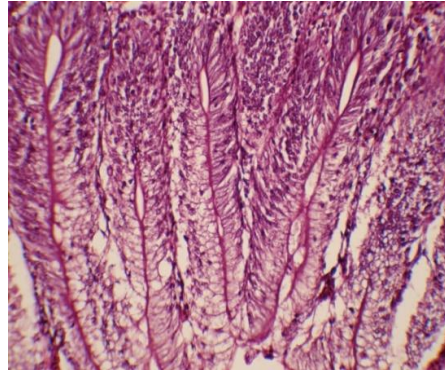


Fig.3 Histology of intestine in *L. sporogenes* and *Micrococcus* sp. treated catfishes showing positive effect of adding probiotic on rapid restoration of the gut atrophy caused by pathogenic bacteria, *Micrococcus* sp. at 100X magnification

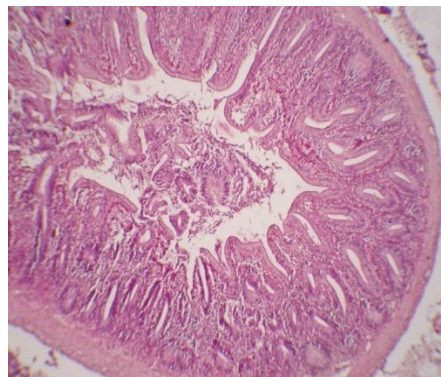
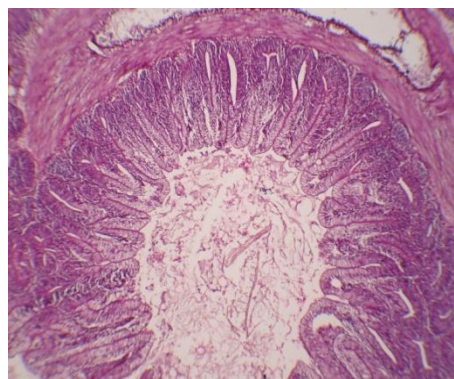


Fig.4 Histology of intestine in *L. sporogenes* treated catfishes showing increased villi number, normal cells of epithelium and lumen with mucus at 100X magnification



In T4 treated group, increases in intestinal folds were observed with slight mononuclear cell infiltration indicating presence of normal

intestinal micro flora (Figure 4). The increase in number of folds caused by *L. sporogenes* is definitely a beneficial effect rendered by the

probiotic on the host. The results clearly indicate that probiotics have beneficial effects on health of catfishes and aid in their disease abatement. The above results indicated that the probiotics strains *L. sporogenes*, had considerable role in the control of bacterial diseases in Indian magur.

In the present investigation effects of probiotic bacteria *L. sporogenes* were observed on intestine of *C. batrachus* as the intestine is main immunological organ containing 50% of all reticulo-endothelial and other immune cells in it, and produces the greatest amount of secretory IgA (Hulsewe, *et al.*, 1999).

According to Isolauri *et al.*, (2001) the gut-associated lymphoid tissue (GALT) represents the largest mass of lymphoid tissue in the human body. According to McGhee *et al.*, (1992) the stimulation of host immunity is related to the ability of microorganisms to adhere to the mucosa and interact with the GALT. The ability of probiotics to adhere to the intestinal cells reduces pathogenic bacteria colonization and thus, contributes to stop pathogenic bacteria translocation (Dahiya *et al.*, 2009, 2012). In the present investigation, *L. sporogenes* beneficially affected the host *C. batrachus* by improving its intestinal microbial environment, and may enable valuable modifications of the immune system. The overall results of present histomorphometric study demonstrated a recovery from the gut atrophy status associated with pathogenic bacteria after inoculation of *L. sporogenes* in catfishes and was associated with normal mucosa lining in the small intestine and similar with the earlier studies carried by using different bacteria i.e. enhanced mucosal trophism by addition of *Streptococcus* and *Lactobacillus* in the fish diet as probiotic bacteria (Dahiya, 2005). According to Gildberg and Mikkelsen, (1998) these results are most probably due to

enhanced short chain fatty acids (SCFA) formation as induced by probiotics. SCFA are the best fuel for the colonocytes and act directly as trophic source for the colonic mucosa. The findings of best recovery of atrophy at the colon were also probably due to short chain fatty acids production. The overall results of present study showed that the addition of probiotic positively influenced a more rapid restoration of the gut atrophy associated with pathogenic bacteria (Figure 3). Although the findings of an experimental study should be transposed to the clinical setting with caution, it could be concluded that *L. sporogenes* if added to a diet enhanced the recovery of the gut atrophy induced by pathogens.

Acknowledgements

We are thankful to Dr. V. P. Sabhlok; Professor and former Head, Department of Zoology and Aquaculture, Chaudhary Charan Singh Haryana Agricultural University, Hisar for providing of laboratory facilities during these investigations.

References

- Allori, C., Agüero G., Ruiz, H. A. P., Nader, O. M. and Perdigon, G. (2000). Gut mucosa morphology and microflora changes in malnourished mice after renutrition with milk and administration of *Lactobacillus casei*. *J. Food Protection*, 63, 83-90. <https://doi.org/10.4315/0362-028X-63.1.83>
- Dahiya, T., Gahlawat, S.K., and Sihag, R.C. (2012). Elimination of Pathogenic Bacterium (*Micrococcus* sp.) by the Use of Probiotics. *Turkish Journal of Fisheries and Aquatic Sciences*, 12, 185-187. https://doi.org/10.4194/1303-2712-v12_1_21

- Dahiya, T. (2005) Survey, isolation and identification of bacterial diseases of fresh water fishes in district Hisar, Haryana (Master's thesis, CCS Haryana Agricultural University Hisar). Retrieved from <http://krishikosh.egranth.ac.in/handle/1/88701>
- Dahiya, T., Ravi, K., Sihag, R.C., (2009). Pathogenicity of bacterial isolates from catfish *C. batrachus* (The Indian Magur), *Journal of The Biosphere*, 1(1): 42-46.
- Gildberg, A. & Mikkelsen, H. (1998). Effects of supplementing the feed to Atlantic cod (*Gadus morhua*) fry with lactic acid bacteria and Immuno-stimulating peptides during a challenge trial with *Vibrio anguillarum*, *Aquacult.*, 167:103–113.
[https://doi.org/10.1016/S0044-8486\(98\)00296-8](https://doi.org/10.1016/S0044-8486(98)00296-8)
- Hulsewe, K. W. E., van Acker B. A. C., Meyenfeldt, M. F., Soeters, P. B. (1999). Nutritional depletion and dietary manipulation: effects on the immune response. *World J. Surgery*, 23(6), 536-544.
<https://doi.org/10.1007/PL00012344>
- Isolauri, E., Sutas, Y., Kankaanpaa, P., Arvilommi, H. and Salminen, S. (2001). Probiotics: effects on immunity. *Am. J. Clin. Nutr.*, 73:444-450.
<https://doi.org/10.1093/ajcn/73.2.444s>
- McGhee, J., Mestscky, M., Dertzkaugh, J., Eldridge, M., Hilrasawa, M. and Kilyono, H. (1992). The mucosal immune system from fundamental concepts to vaccine development. *Vaccine*, 10:75-88.
[https://doi.org/10.1016/0264-410X\(92\)90021-B](https://doi.org/10.1016/0264-410X(92)90021-B)
- Pluske, J. R., Hampson, D. J. and Williams, I. H. (1997). Factors influencing the structure and function of the small intestine in the weaned pig: a review. *Livest. Prod. Sci.*, 51:215-236.
[https://doi.org/10.1016/S0301-6226\(97\)00057-2](https://doi.org/10.1016/S0301-6226(97)00057-2)

How to cite this article:

Tejpal Dahiya, Ravikant and Gajender Singh. 2020. Effect of *Lactobacillus sporogenes* Probiotic Bacteria on the Intestinal Histopathology of Indian Magur (*C. batrachus*) Inoculated with Pathogenic Bacteria, *Micrococcus* sp.. *Int.J.Curr.Microbiol.App.Sci.* 9(02): 2344-2348. doi: <https://doi.org/10.20546/ijcmas.2020.902.266>