

Case Study

<https://doi.org/10.20546/ijcmas.2019.811.168>

## Clinico-Pathological Study on Intraocular Transmissible Venereal Tumour in Dogs – A Review of Four Cases

V. Kumar\*, S. Hemalatha, C. Balachandran and Mohammed Safizama

Department of Veterinary Pathology, Madras Veterinary College, Tamil Nadu Veterinary and Animal Sciences University, Chennai-600 007, India

\*Corresponding author

### ABSTRACT

#### Keywords

TVT, Dog, Ocular, Vincristine

#### Article Info

##### Accepted:

12 October 2019

##### Available Online:

10 November 2019

Ocular TVT was encountered in four dogs along with multilobulated masses on the external genitalia, and subcutaneous tissues. The haematobiochemical changes were within the normal range. FNAC and histopathological examination were performed. Cytological smears taken from the masses showed moderate to high cellularity with discrete cells. Histopathologically, neoplastic cells were seen arranged as large sheets with thin delicate strands of fibrous stroma. The surface epithelium showed thinning due to compression of tumour. Based on cytological and histopathological examination it was confirmed as Transmissible Venereal Tumour (TVT). It was treated with Vincristine @ 0.025 mg/kg/b.wt. intravenously.

### Introduction

Transmissible Venereal Tumour (TVT) is proliferative verrucous, papillary, or nodular masses and spread to all over the body including eye by contact with the transplantation of tumour cells (Meuten, 2002). Diagnosis of TVT either by Fine needle aspiration cytology (FNAC), impression smear and histopathology. Cytologically TVT neoplastic cells are round, ovoid and polyhedral in shape. Cellularity is high with homogeneous round individual cells arranged

in a sheet-like pattern (Kirthiga *et al.*, 2005). Treatment of TVT by single agent therapy Vincristine is more effective, safe and cost effective chemotherapeutic agent resulting in cure even in TVT dogs with extragenital metastasis. There are many authors recorded cases of extra genital TVT in dogs with successful diagnosis and treated by Vincristine (Kumar *et al.*, 2014).

The present paper recorded the cases of ocular TVT, clinico pathological studies and its successful therapeutic management.

## Materials and Methods

Tissue samples from dogs were collected from cases of skin tumours which attended Small Animal Clinics of Madras Veterinary College Teaching Hospital, Chennai. Blood was collected to rule out any changes in the haematology and serum biochemistry. Smears prepared from FNAC and imprints from cutaneous tumours were either air dried or wet fixed in absolute isopropanol for 30 minutes and stained by Leishman–Geimsa (LG) and Haematoxylin and Eosin (H&E) stains (Kirthiga *et al.*, *loc.cit*). Tissue samples fixed in 10% neutral buffered formalin were embedded in paraffin and 3-5 µm thickness sections were cut and stained with H&E (Bancroft and Gamble, 2008).

## Results and Discussion

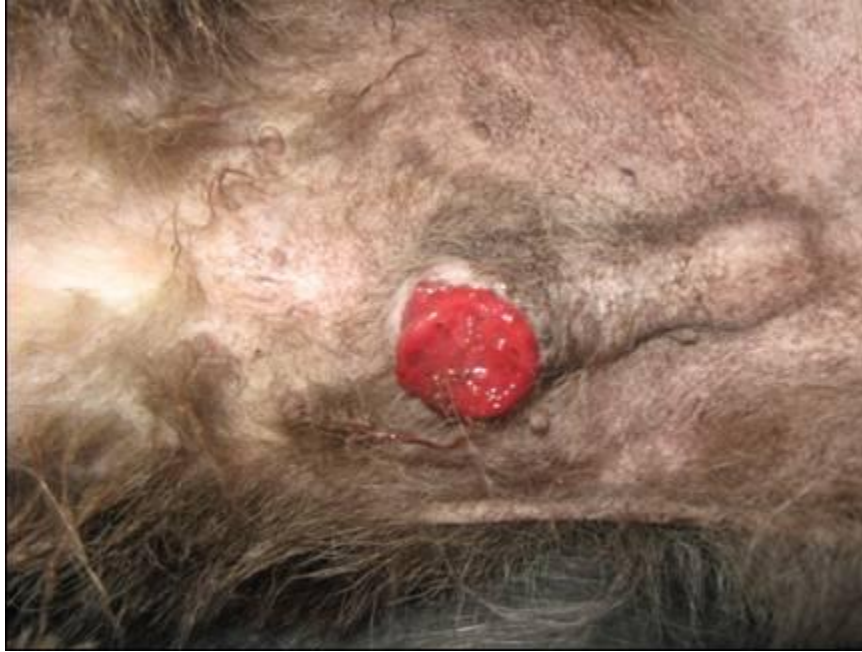Ocular TVT was encountered in 4 cases of out of 11 recorded TVT cases. Two cases were observed in Spitz and one each in Labrador and Doberman dogs. Age of affected animals varied from 3 to 15 years with a mean age of 8.36 years. Three males and one female were affected. The tumour masses were found at the base of the penis, middle of the penis and glans penis (Fig. 1), neck, prepuce, hock joint of males and vulva of female and the masses were also noticed in the eyes (Fig. 2) of both the sexes. Grossly, the TVT masses in other areas were irregular, cauliflower-like, reddish, soft and had a tendency to bleed. Ophthalmic examination revealed a pink mass protruding from the sclera at the superior temporal area of the eye and filling the anterior chamber of the right eye in three case left eye in one case. The haematobiochemical changes were within the normal range. Cytological examination

revealed high cellularity with round cells. The cytoplasm was basophilic with vacuolation (Fig. 3). The nucleus was variable sized and contained one or more prominent nucleoli with coarse chromatin. Mitotic figures were also seen. These findings concurred with those of (Kirthiga *et al.*, *loc.cit*). Histopathological examination revealed TVT cells were seen arranged as sheets with thin delicate strands of fibrous stroma. The cytoplasm was eosinophilic. Nuclei were large and vesicular with centrally or marginally placed nucleoli.

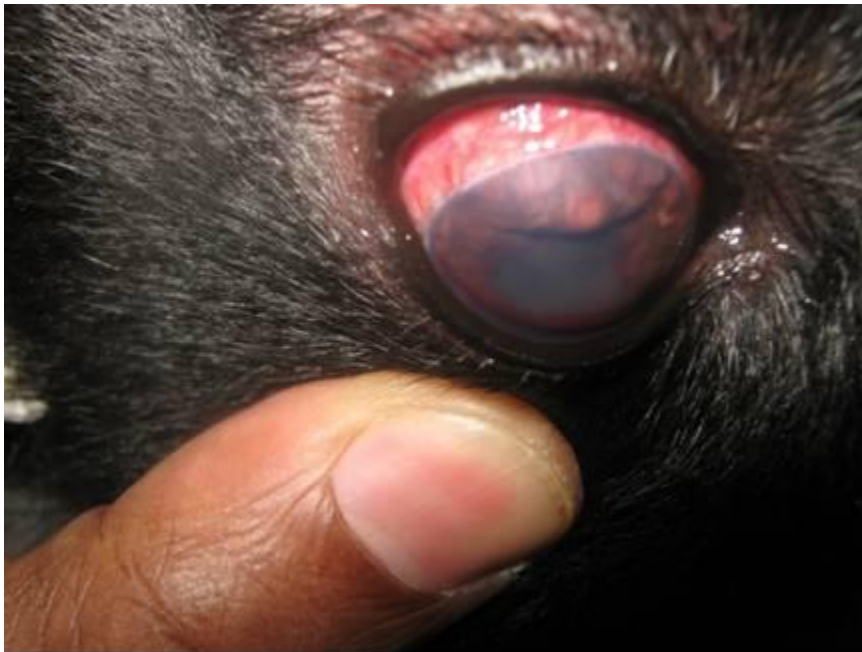Binucleated cells, pleomorphic nuclei and mitotic figures (Fig. 4) were common. Infiltration of lymphocytes, neutrophils and plasma cell were also observed. (Kumar *et al.*, *loc.cit*) also recorded similar findings. The chemotherapy using inj. Vincristine @ 0.025 mg/kg/b.wt. intravenously was injected on 1<sup>st</sup> presenting day at weekly interval for 6 weeks for regression of the subcutaneous growth, ocular growth and also to avoid the recurrence of tumour. The treatment with vincristine lead to complete regression of subcutaneous growth and eye lesions (Fig. 5). The TVT growth pattern in eye is most infiltrative origin. In these cases were an implantation of TVT cells directly over ocular surface might be the tumour growth was outwardly and protruding from the eye across sclera. Similar subcutaneous TVT have been recorded, diagnosed and treated by (Kumar *et al.*, *loc.cit*) and third eye lid TVT lesions treated by (Jewel Milo and Elisabeth Snead, 2014).

The present study, ocular TVT was successfully diagnosed by cytological and histopathological techniques and it was also treated by inj. Vincristine @ 0.025 mg/kg/b.wt. intravenously for 6 weeks.

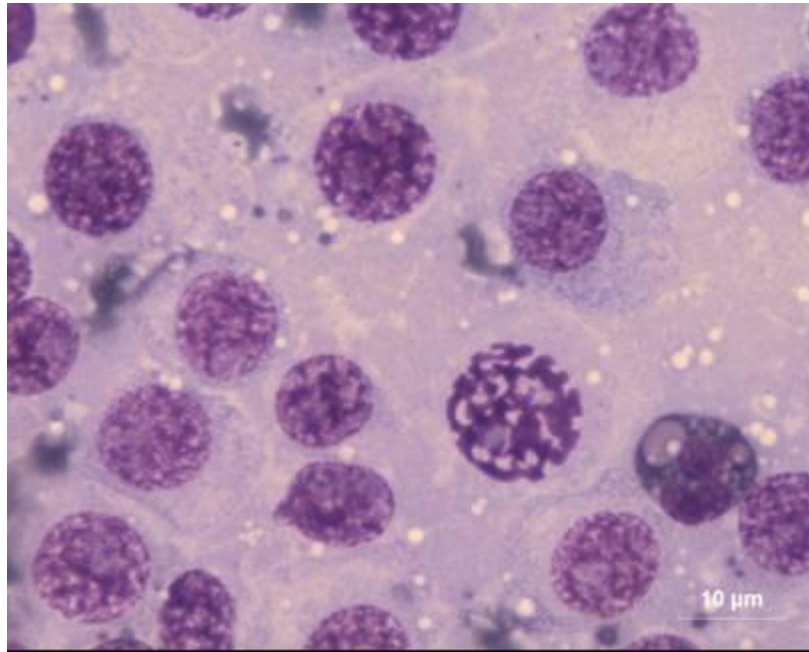
**Fig.1** TVT-Gland penis-Doberman, male, 15 years



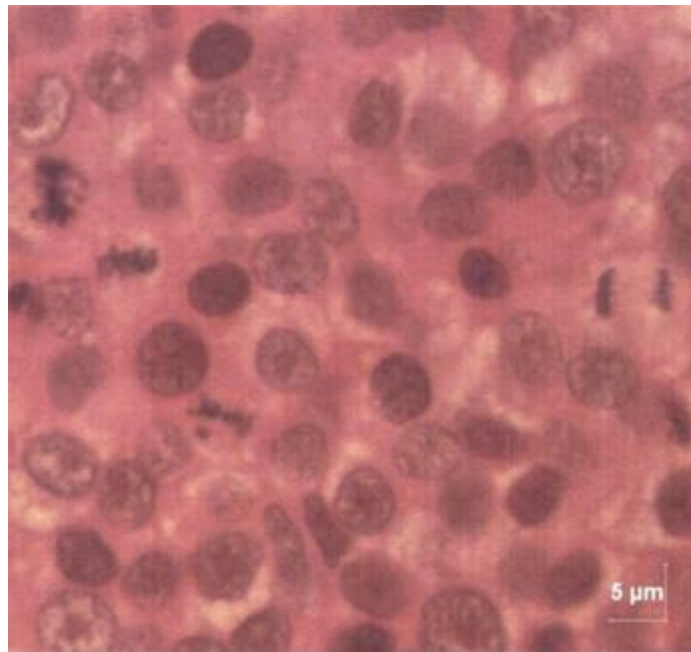
**Fig.2** TVT-Ocular-Before Treatment



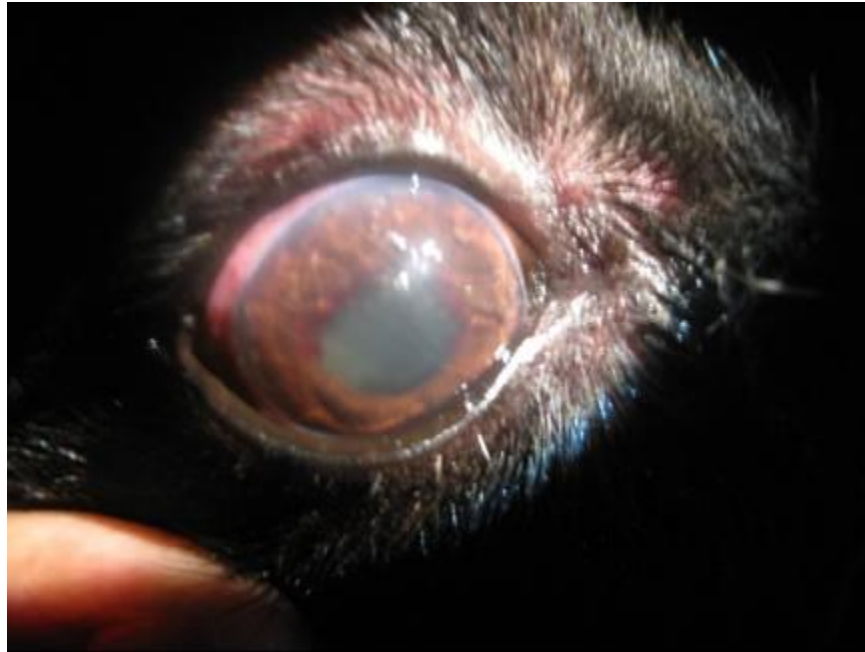
**Fig.3** TVT-Cytology-Basophilic, vacuolated cytoplasm and mitotic figure LG Bar = 10  $\mu$ m



**Fig.4** TVT-Mitotic figures H&E Bar=5  $\mu$ m



**Fig.5** TVT-ocular-after treatment



## References

- Bancroft, J.D. and Gamble, M. (2008). Theory and Practice of Histological Techniques. 6<sup>th</sup> Edn., Churchill Living stone, London.
- Donald J. Meuton, (2002). Tumours in Domestic Animals. 4<sup>th</sup> ed. Iowa state press, 2121 state avenus, Ames, Iowa 50014. P. 115-117.
- Jewel milo and Elisabeth snead. (2014). A case of ocular canine transmissible venereal tumours. *Can. Vet. J.* 55:1245-1249.
- Krithiga, K., Murali Manohar, B. and Balachandran, C. (2005). Cytological and histo pathological study on cutaneous round cell tumours in canines. *Indian J. Vet. Pathol.*, 29 (1): 38-41.
- Kumar, V., Hemalatha, S, Balachandran, C and Jayaprakash, R. (2014). An unusual case of primary subcutaneous venereal granuloma (TVT) in a German shepherd and its successful therapeutic Management. *Indian. Vet. J.* 91(06): 84-86.

## How to cite this article:

Kumar, V., S. Hemalatha, C. Balachandran and Mohammed Safizama. 2019. Clinico-Pathological Study on Intraocular Transmissible Venereal Tumour in Dogs – A Review of Four Cases. *Int.J.Curr.Microbiol.App.Sci.* 8(11): 1432-1436.  
doi: <https://doi.org/10.20546/ijcmas.2019.811.168>