

Original Research Article

<https://doi.org/10.20546/ijcmas.2018.703.175>

## Gross and Ultra-Structural Studies on the Large Intestine of Uttara Fowl

K. Pandit<sup>1\*</sup>, B.S. Dhote<sup>1</sup>, D. Mahanta<sup>1</sup>, S. Sathapathy<sup>2</sup>, S. Tamilselvan<sup>1</sup>,  
M. Mrigesh<sup>1</sup> and S. Mishra<sup>3</sup>

<sup>1</sup>Department of Veterinary Anatomy, C.V.A.Sc., GBPUAT, Pantnagar – 263 145,  
Uttarakhand, India

<sup>2</sup>Department of Veterinary Anatomy and Histology, C.V.Sc. and A.H., OUAT,  
Bhubaneswar – 751003, Odisha, India

<sup>3</sup>Division of Veterinary Pathology, ICAR-Indian Veterinary Research Institute,  
Izzatnagar – 243 122, Bareilly, U.P, India

\*Corresponding author

### ABSTRACT

The present study was conducted on 24 Uttara fowl birds. The gross and ultra-structural features with their age-related changes in the large intestine were studied. The length and weight of caeca and colorectum and their diameter and thickness at proximal, middle and distal portions in all the age groups increased with advancing age. The left caeca were slightly longer and heavier than right caecum in all studied age groups. Scanning electron microscopy revealed that the proximal portion of caecum possessed finger like villi with dome shaped tip in day old bird which later showed tapering peak shaped tip. Villi were absent in distal portion of caecum and only folds were observed with wavy pattern bearing goblet pits. Villi in colorectum were tongue shaped with a curved tip and corrugated surface.

#### Keywords

Gross, Morphometry,  
Scanning electron  
microscopy, Large  
intestine, Uttara fowl

#### Article Info

Accepted:  
12 February 2018  
Available Online:  
10 March 2018

### Introduction

Uttara fowl is unique in its adaptation to the agro-climatic conditions of their habitat (Kaur *et al.*, 2010). Their germplasm is unexplored and possess various potential genes responsible for survival in rough conditions of hilly terrain of Uttarakhand. Uttara fowl is mainly found in Kumaon region of Uttarakhand. This breed has evolved through natural selection in indigenous agro-ecological

conditions and is well adapted to the local environment. There is very little information available on characteristics of local hill fowl of Uttarakhand. However, existence of different strains of Uttara fowl has been reported (Pant *et al.*, 2007). Uttara fowls have low cholesterol content in their blood which makes it suitable for heart patients and obese people. It has high glucose level in its blood due to more energy requirement at high altitude, more activity and more flying

tendency than commercial birds (Kaur, 2007). Fundamentals for the production performance in a poultry flock are their genetic merit, management and health. The study of avian gastrointestinal tract anatomy is still in its infancy and needs to be further explored as it plays a vital role in feed utilization which ultimately affects the overall productivity of the bird. There are many nutritional reports on the avian intestinal system but very little is known about the detailed anatomy of large intestine (Bayer *et al.*, 1981; Turk, 1982). Different fields of veterinary and animal sciences are dependent on the anatomy and histology of body organs (Argenzio, 1980). The large intestine due to its lymphatic tissue aggregates in the colon and caeca has a major immunological role (Ushakumary *et al.*, 2002). Caecal functioning is still only partly understood (McNab, 1973, Braun and Duke, 1989). However, research of many decades has revealed its role in energy balance and osmoregulation which involves absorption of material from the caecum. Caeca may also serve as the site for several different functions, especially digestion of small food particles, absorption of nutrients, production of immunoglobulins, utilization and absorption of water and metabolism of uric acid into amino acids. Caecotomy has shown to increase the water intake and increased excretion of water in faeces (Son *et al.*, 2000; 2002). Persual of literature revealed limited information pertaining to the large intestine of Uttara fowl. Keeping in view the above consideration, the present study was conducted to study detailed gross morphology, gross morphometry and ultrastructure of large intestine of Uttara fowl.

## **Materials and Methods**

### **Experimental birds**

To carry out study on structural organization of the large intestine of Uttara fowl, a total of

twenty-four birds were purchased from Instructional Poultry Farm, G.B Pant University of Agriculture and Technology, Pantnagar. All the birds were vaccinated against Newcastle disease and Infectious Bursal disease with primary (for both) and booster (for Newcastle disease) doses.

### **Experimental design**

Based on age, the birds were divided into four groups viz. day old, 7, 28 & 112 days old birds with six birds in each age group. On each observation day, six birds were utilized for gross morphometrical features of the large intestine. Two birds were used for ultra-structural investigations.

### **Gross morphological and morphometric studies**

The birds were sacrificed by severing the carotid artery and jugular veins. Feathers were removed manually and the intestine was carefully dissected out. The weight of the various parts of the large intestine was recorded using digital balance (Sartorius, 2014). Thereafter, the caecal length of the bird (right and left), outer diameter of caecum, thickness of caecum wall, inner diameter of caecum, length of colorectum, outer diameter of colorectum, thickness of colorectum wall and inner diameter of colorectum were recorded by using digital vernier calipers (0-150mm).

### **Ultra-structural studies**

Scanning Electron Microscope (SEM) studies was carried out as per standard method at SEM facility GBPUAT Pantnagar. Electron microscopic studies were carried out as per standard method described by Electron microscopic manual of AIIMS, New Delhi, Malorni *et al.*, (1998) and Chauhan (2003) with some modifications and the steps

involved were fixation, washing, dehydration, drying, mounting, sputter coating, viewing and photography.

## Results and Discussion

### Gross morphology and morphometry

The large intestine of Uttara fowl comprised of a paired, enlarged caeca (Fig. 1) also reported by Sisson *et al.*, (1953), Clench (1999), Hassouna (2001), Samte (2008), Nasrin *et al.*, (2012), Mahmud *et al.*, (2015). A short straight colorectum was present continuous with the ileum and the cloaca. In the present study the sampling is done from ileo-colic junction to cloaca and there is no differentiation between colon and rectum the term colorectum will be used instead of colon same was reported by Mcleod (1939) and Romanoff (1960) in chicken, Nasrin *et al.*, (2012) in broiler, Mahmud *et al.*, (2015) in Indigenous Nigerian Chicken. While Samte (2008) in Kadaknath fowl and Nickel *et al.*, (1977) in chicken, reported that a short straight colon continuous with the ileum and the cloaca whereas Getty (1975) and Majeed *et al.*, (2009) reported the terminal segment of large intestine as rectum. In present study, the entire caecal length was divided into three main portions: Proximal, Middle and Distal as also reported by Mahmud *et al.*, (2015) in Negerian chicken Nasrin *et al.*, (2012), Hassouna (2001) and Pilz (1937) in chicken. The diameter of both right and left caecum in Uttara fowl was minimum at its base and increases along the length as they run towards the distal portion. However, the wall thickness was more in the proximal portion and decreases along the length caudally. These findings were in accordance with observation of Pilz (1937), Hodges (1974), Hassouna (2001) and Nasrin *et al.*, (2012) in chicken. The caecum was found to be attached to small intestine by two ileocecal ligaments as also reported by Nickel *et al.*, (1977). The enlarged

caeca was observed as reported by King and McLelland (1975) in chicken. The average length of the right caecum at day 1, 7, 28 and 112 was  $3.70\pm 0.139$ ,  $5.84\pm 0.17$ ,  $8.84\pm 0.25$  and  $16.04\pm 0.32$  cm respectively (Table 1, Fig. 2). Nasrin *et al.*, (2012) recorded the average length of each caeca as  $3.625\pm 0.217$ ,  $10.25\pm 0.645$  and  $18.125\pm 1.732$  cm at Day 1, Day 14 and Day 28 respectively. Samte (2008) recorded average length of right caecum at day 1, 7, 28 and 112 as 4.52 cm, 6.50, 9.28 and 17.24 cm respectively in Kadaknath fowl. Pilz (1937), Bradley and Grahame (1960), Hodges (1964), King and McLelland (1975), Nickel *et al.*, (1977), Ghosh (1995) and Verma *et al.*, (1998) recorded the length of caeca in 112 days old bird as 14 to 23.5, 16 to 18, 12 to 16, 14 to 23.5, 12 to 25, 15 and 17.2 cms respectively in chicken. The left caeca was slightly longer than corresponding right caeca in all the studied age groups. The average length of left caeca at day 1, 7, 28 and 112 was  $3.71\pm 0.163$ ,  $6.0\pm 0.12$ ,  $9.52\pm 0.26$  and  $16.84\pm 0.29$  cm, respectively (Table 1, Fig. 2). On comparing mean length of right caeca and left caeca in all the age groups it is inferred that the length of left caeca is greater than that of right caeca. Samte (2008) recorded the length of left caecum in Kadaknath fowl at day 1, 7, 28 and 112 as 5.17, 7.0, 10.14 and 17.81 cms respectively which are in line with the present findings that the length of left caecum is slightly greater than corresponding right caecum. The length of left caeca in Uttara fowl birds of all ages were longer than their respective right caeca also correspond to the findings of Ewa Dziala-Szczepanczyk and Katarzyna Betlejewska (2003) in Black scoter (*Melanitta nigra*) and Ewa Dziala-Szczepanczyk (2006) in Long tailed ducks. The average length of the colorectum at day 1, 7, 28 and 112 was  $2.37\pm 0.13$ ,  $3.49\pm 0.12$ ,  $4.22\pm 0.21$  and  $7.12\pm 0.10$  cm respectively (Table 1, Fig. 2) which is very close and in accordance with the findings of Samte (2008) in Kadaknath fowl who recorded average

length of the colon at day 1, 7, 28 and 112 as 2.37, 3.42, 4.22 and 7.11 cm respectively. In chicken, Nasrin *et al.*, (2012) reported that the colorectum was the terminal part of the intestine, passing between the ileo-cecal junction and the cloaca. It was comparatively short and straight and had thick, muscular walls. The average length of colorectum being  $2.925 \pm 0.119$ ,  $6.82 \pm 0.011$  and  $8.83 \pm 0.037$  cms at day1, 14 and 28 respectively. The colorectum of Uttara fowl was short and nearly straight lying ventral to the vertebrae leading from the ileocaecal junction to the cloaca. The length of the colorectum in adult Uttara fowl bird observed is similar with that of Pilz (1937), Hodges (1974), Nickel *et al.*, (1977) and Verma *et al.*, (1998) in adult fowl where the length were reported to be 8 to 11 cm, 8 cm, 8 to 11 cm and 7 to 8 cm, respectively.

The average weight of the right caecum at day 1, 7, 28 and 112 was  $0.13 \pm 0.02$ ,  $0.20 \pm 0.03$ ,  $0.76 \pm 0.05$  and  $4.72 \pm 0.57$  g respectively. The average weight of the right caecum recorded by Samte (2008) at day 1, 7, 28 and 112 was 0.17, 0.24, 0.79 and 4.14 g respectively in Kadaknath fowl. Nasrin *et al.*, (2012) reported that the average weight of caeca was  $0.15 \pm 0.035$ ,  $1.99 \pm 0.143$  and  $5.53 \pm 0.787$  g, at day 1, 14 and 28 respectively. These results are in concurs with present studies. The average weight of the left caecum at day 1, 7, 28 and 112 was  $0.15 \pm 0.02$ ,  $0.23 \pm 0.04$ ,  $0.79 \pm 0.03$  and  $4.79 \pm 0.60$  g respectively. The average weight of the left caecum recorded by Samte (2008) at day 1, 7, 28 and 112 was 0.14, 0.25, 0.76 and 3.58 g respectively. The average weight of the colorectum at day 1, 7, 28 and 112 was  $0.14 \pm 0.01$ ,  $0.25 \pm 0.01$ ,  $0.66 \pm 0.04$  and  $2.96 \pm 0.21$  g respectively. The average weight of the colon according to Samte (2008) at day 1, 7, 28 and 112 was 0.13, 0.25, 0.66 and 2.96 g respectively in Kadaknath fowl. Nasrin *et al.*, (2012) recorded that the average weights of colorectum was

$0.48 \pm 0.022$ ,  $1.95 \pm 0.212$  and  $4.66 \pm 0.018$  gm, at day1, 14 and 28 respectively.

The outer diameter (average) of proximal, middle and distal portions of right caecum was  $1.46 \pm 0.17$ ,  $1.79 \pm 0.07$ ,  $2.19 \pm 0.03$  mm for day-old;  $1.88 \pm 0.08$ ,  $2.28 \pm 0.13$ ,  $2.40 \pm 0.11$  mm for 7 days;  $4.17 \pm 0.09$ ,  $4.24 \pm 0.07$ ,  $6.68 \pm 0.09$  mm for 28 days and  $5.28 \pm 0.07$ ,  $5.33 \pm 0.08$ ,  $10.66 \pm 0.19$  mm for 112 days old Uttara fowl, respectively (Table 2, Fig. 3). According to Samte (2008) the outer diameter (average) of the right caecum at the proximal middle and distal portions was 1.137, 1.515, 2.308 mm for day-old; 1.487, 2.677, 3.230 mm for 7 days; 3.742, 4.970, 6.953 mm for 28 days and 4.011, 5.057, 9.541 mm for 112-days old Kadaknath fowl respectively. King and McLelland (1975) reported that the outer diameter of caecum at proximal, middle and distal portions was 0.3 to 0.5, 0.5 to 0.7 and 0.8 to 1.2 cm, respectively. The wall thickness (average) of proximal, middle and distal portions of right caecum was  $0.74 \pm 0.01$ ,  $0.57 \pm 0.04$ ,  $0.29 \pm 0.01$  mm for day old;  $0.76 \pm 0.01$ ,  $0.74 \pm 0.02$ ,  $0.59 \pm 0.01$  mm for 7 days;  $1.48 \pm 0.07$ ,  $1.41 \pm 0.06$ ,  $1.16 \pm 0.02$  mm for 28 days and  $1.94 \pm 0.12$ ,  $1.85 \pm 0.04$ ,  $1.36 \pm 0.02$  mm for 112 days old Uttara fowl, respectively (Table 3, Fig. 4). Samte (2008) recorded that the wall thickness (average) of the right caecum at the proximal, middle and distal portions as 0.769, 0.611, 0.251 mm for day-old; 0.760, 0.723, 0.5571 mm for 7 days; 1.455, 1.269, 1.110 mm for 28 days and 1.896, 1.738, 1.392 mm for 112-days old Kadaknath fowl respectively. These results are in accordance with present findings. The inner diameter (average) of proximal, middle and distal portion of right caecum was  $0.72 \pm 0.01$ ,  $1.24 \pm 0.01$ ,  $1.89 \pm 0.01$  mm for day old;  $1.00 \pm 0.01$ ,  $1.46 \pm 0.06$ ,  $1.84 \pm 0.01$  mm for 7 days;  $2.68 \pm 0.02$ ,  $2.84 \pm 0.03$ ,  $5.12 \pm 0.03$  mm for 28 days and  $3.55 \pm 0.02$ ,  $3.54 \pm 0.01$ ,  $9.34 \pm 0.04$  mm for 112 days old Uttara fowl, respectively (Table 4, Fig. 5).

**Table.1** Mean length of various segments of large intestine (cm)

Various segments	Age Group			
	Day 1	Day 7	Day 28	Day 112
<b>Right caecum</b>	3.70±0.139	5.84±0.17	8.84±0.25	16.04±0.32
<b>Left caecum</b>	3.71±0.163	6.00±0.12	9.52±0.26	16.84±0.29
<b>Colorectum</b>	2.37±0.13	3.49±0.12	4.22±0.21	7.12±0.10

**Table.2** Mean outer diameter of various segments of large intestine (cm)

Various segments		Age Group			
		Day 1	Day 7	Day 28	Day 112
<b>Right Caecum</b>	Proximal portion	1.46±0.17	1.88±0.08	4.17±0.09	5.28±0.07
	Middle portion	1.79±0.07	2.28±0.13	4.24±0.07	5.33±0.08
	Distal portion	2.19±0.03	2.40±0.11	6.68±0.09	10.66±0.19
<b>Left Caecum</b>	Proximal portion	1.49±0.05	1.89±0.06	4.21±0.13	4.82±0.04
	Middle portion	1.77±0.03	2.54±0.11	4.89±0.09	7.17±0.09
	Distal portion	2.37±0.02	3.51±0.18	7.30±0.09	12.10±0.07
<b>Colorectum</b>	Proximal portion	1.75±0.04	2.83±0.19	4.74±0.15	6.74±0.05
	Middle portion	2.35±0.12	2.94±0.05	5.43±0.20	7.09±0.04
	Distal portion	2.53±0.15	3.36±0.12	5.63±0.14	8.64±0.17

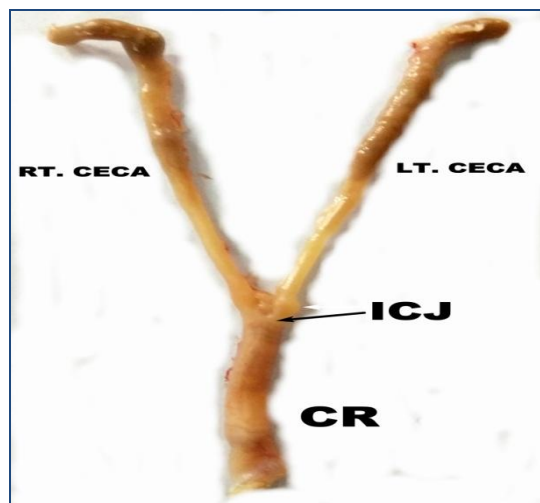
**Table.3** Mean wall thickness of various segments of large intestine (cm)

Various segments		Age Group			
		Day 1	Day 7	Day 28	Day 112
<b>Right Caecum</b>	Proximal portion	0.74±0.01	0.76±0.01	1.48±0.07	1.94±0.12
	Middle portion	0.57±0.04	0.74±0.02	1.41±0.06	1.85±0.04
	Distal portion	0.29±0.01	0.59±0.01	1.16±0.02	1.36±0.02
<b>Left Caecum</b>	Proximal portion	0.91±0.05	0.98±0.04	1.55±0.09	1.85±0.03
	Middle portion	0.68±0.03	0.69±0.02	1.35±0.01	1.74±0.03
	Distal portion	0.59±0.02	0.63±0.01	1.10±0.01	1.39±0.03
<b>Colorectum</b>	Proximal portion	0.42±0.05	0.89±0.03	1.28±0.16	1.75±0.07
	Middle portion	0.69±0.02	1.08±0.03	1.55±0.01	1.84±0.07
	Distal portion	0.96±0.05	1.35±0.08	1.73±0.05	1.83±0.03

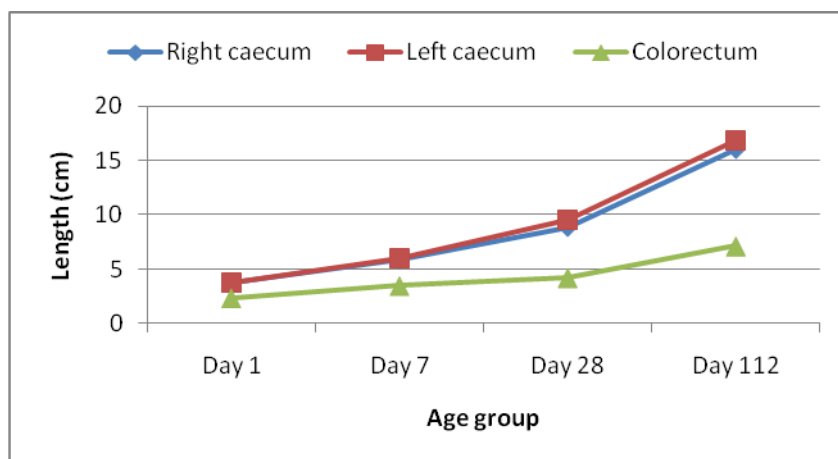
**Table.4** Mean inner diameter of various segments of large intestine (cm)

Various segments		Age Group			
		Day 1	Day 7	Day 28	Day 112
<b>Right Caecum</b>	Proximal portion	0.72±0.01	1.00±0.01	2.68±0.02	3.55±0.02
	Middle portion	1.24±0.01	1.46±0.06	2.84±0.03	3.54±0.01
	Distal portion	1.89±0.01	1.84±0.01	5.12±0.03	9.34±0.04
<b>Left Caecum</b>	Proximal portion	0.57±0.01	0.92±0.01	1.97±0.02	2.95±0.01
	Middle portion	1.19±0.03	2.64±0.03	3.58 ±0.09	5.42±0.06
	Distal portion	2.13±0.05	2.87±0.02	6.27±0.05	10.65±0.04
<b>Colorectum</b>	Proximal portion	1.33±0.03	1.95±0.02	3.51±0.09	4.79±0.06
	Middle portion	1.65±0.01	1.81±0.04	3.82±0.05	5.29±0.04
	Distal portion	1.21±0.04	2.07±0.05	3.58±0.13	6.54±0.11

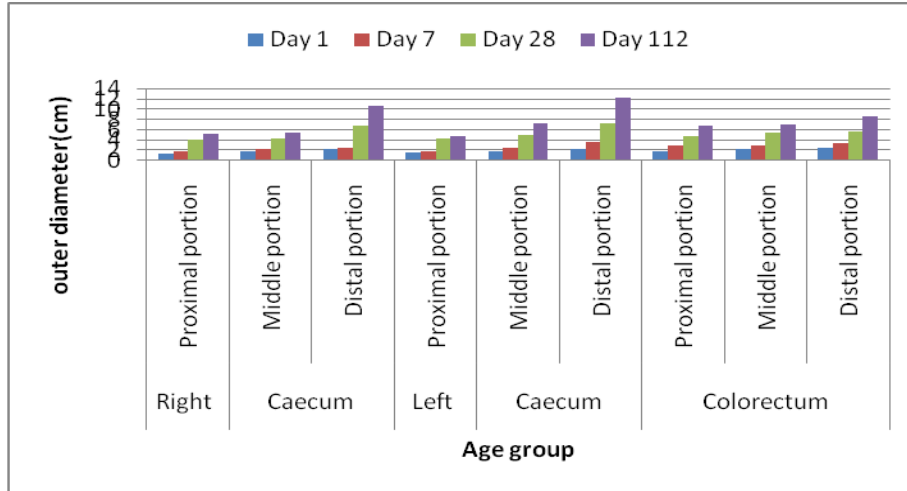
**Fig.1** Photograph of 28-day old large intestine with left and right caecum opening in colorectum (CR) at ileocecal junction (ICJ)



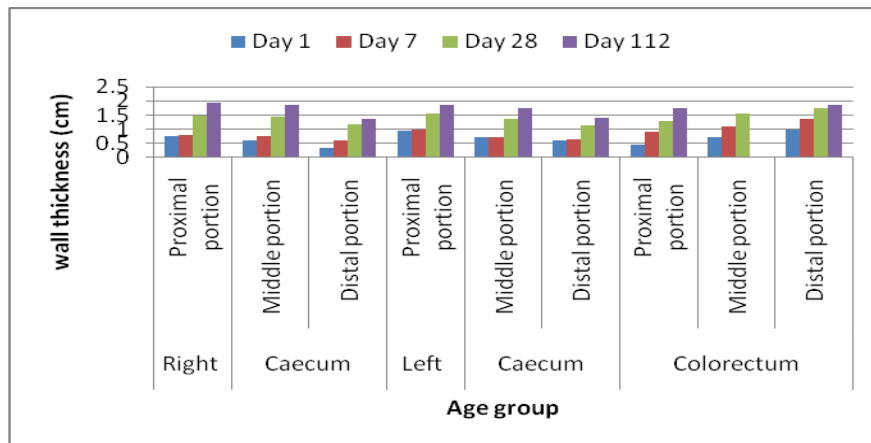
**Fig.2** Comparison of length of various segments of large intestine (cm)



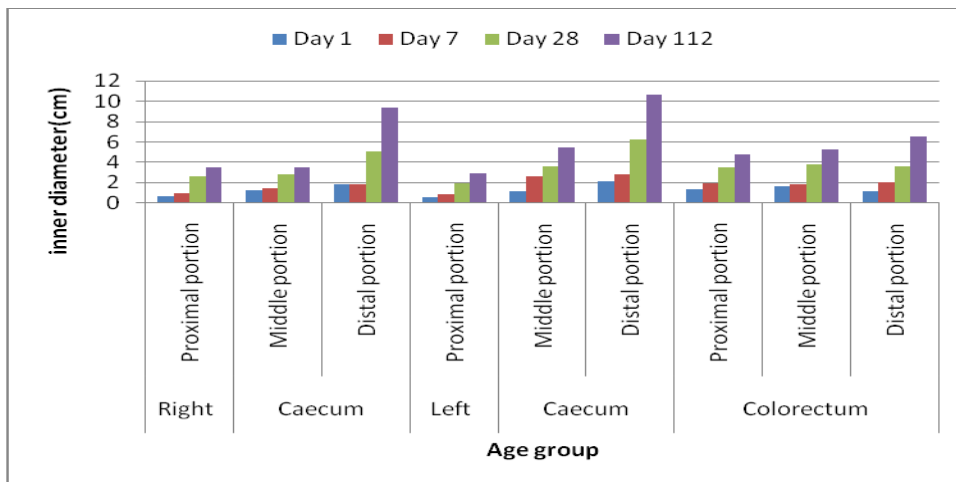
**Fig.3** Comparison of outer diameter of various segments of large intestine (cm)




**Fig.4** Comparison of wall thickness of various segments of large intestine (cm)



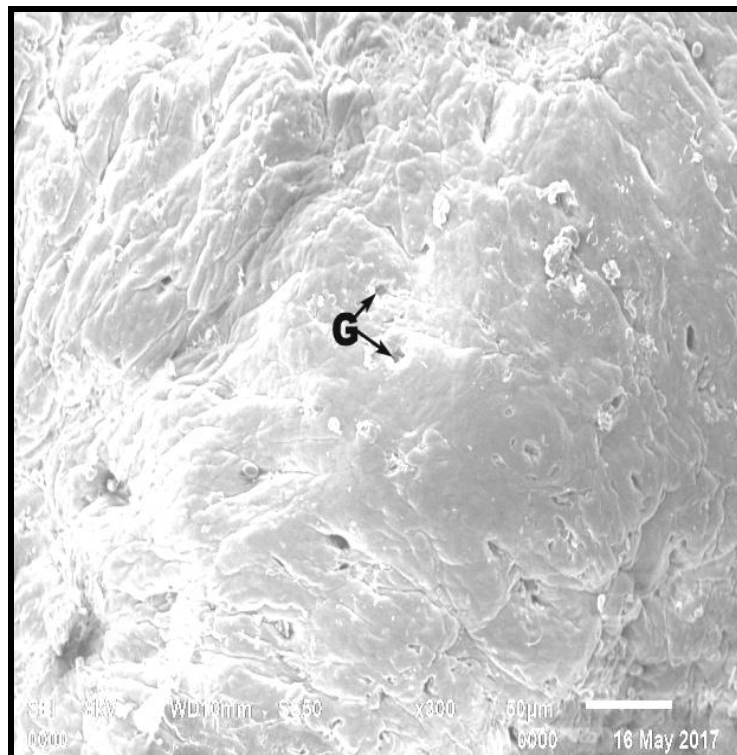
**Fig.5** Comparison of inner diameter of various segments of large intestine (cm)



**Fig.6** Scanning electron micrograph of proximal caecum in day old bird showing finger like villi (V) with horizontal recesses on the surface




**Fig.7** Scanning electron micrograph of distal caecum in day old bird showing irregular surface with goblet cell pits






**Fig.8** Scanning electron micrograph of distal caecum in day old bird showing mucosal folds with wavy pattern



**Fig.9** Scanning electron micrograph showing tongue shaped villi with curved tip in colorectum of 112 day old bird



Samte (2008) recorded inner diameter (average) of the right caecum at the proximal, middle and distal portions as 0.368, 0.904, 2.057 mm for day-old; 0.727, 1.954, 2.752 mm for 7 days; 2.287, 3.701, 5.843 mm for 28 days and 2.115, 3.319, 8.149 mm for 112-days of Kadaknath fowl respectively. The outer diameter (average) of proximal, middle and distal portion of left caecum was

1.49±0.05, 1.77±0.03, 2.37±0.02 mm for day old; 1.89±0.06, 2.54±0.11, 3.51±0.18 mm for 7 days; 4.21±0.13, 4.89±0.09, 7.30±0.09 mm for 28 days and 5.82±0.07, 7.17±0.08, 12.10±0.19 mm for 112 days old Uttara fowl, respectively (Table 2, Fig. 3). Samte (2008) recorded outer diameter (average) of the left caecum at the proximal, middle and distal portions as 1.265, 1.405, 2.206 mm for day-

old; 1.787, 3.138, 3.372 mm for 7 days; 3.730, 4.947, 7.291 mm for 28 days and 4.802, 7.045, 12.01 mm for 112-days old Kadaknath fowl respectively. The wall thickness (average) of proximal, middle and distal portions of left caecum was  $0.91\pm 0.05$ ,  $0.68\pm 0.03$ ,  $0.59\pm 0.02$  mm for day old;  $0.98\pm 0.04$ ,  $0.69\pm 0.02$ ,  $0.63\pm 0.01$  mm for 7 days;  $1.55\pm 0.09$ ,  $1.35\pm 0.01$ ,  $1.10\pm 0.01$  mm for 28 days and  $1.85\pm 0.03$ ,  $1.74\pm 0.03$ ,  $1.39\pm 0.03$  mm for 112 days old Uttara fowl, respectively (Table 3, Fig. 4). Samte (2008) recorded wall thickness (average) of the left caecum at the proximal, middle and distal portions as 0.796, 0.609, 0.245 mm for day old; 0.755, 0.715, 0.590 mm for 7 days; 1.475, 1.270, 1.097 mm for 28 days and 1.846, 1.725, 1.380 mm for 112-days old Kadaknath fowl respectively. The inner diameter (average) of proximal, middle and distal portion of left caecum was  $0.57\pm 0.01$ ,  $1.19\pm 0.03$ ,  $2.13\pm 0.05$  mm for day old;  $0.92\pm 0.01$ ,  $2.64\pm 0.03$ ,  $2.87\pm 0.02$  mm for 7 days;  $1.97\pm 0.02$ ,  $3.58\pm 0.09$ ,  $6.27\pm 0.05$  mm for 28 days and  $2.95\pm 0.01$ ,  $5.42\pm 0.06$ ,  $10.65\pm 0.04$  mm for 112 days old Uttara fowl, respectively (Table 4, Fig. 5). Samte (2008) recorded the inner diameter (average) of the left caecum at the proximal, middle and distal portions of left caecum as 0.468, 0.796, 1.961 mm for day-old; 1.032, 2.423, 2.782 mm for 7 days; 2.255, 3.677, 6.194 mm for 28 days and 2.955, 5.322, 10.618 mm for 112-days old Kadaknath fowl respectively.

The outer diameter (average) of proximal, middle and distal portion of colorectum was  $1.75\pm 0.04$ ,  $2.35\pm 0.12$ ,  $2.53\pm 0.15$  mm for day old;  $2.83\pm 0.19$ ,  $2.94\pm 0.05$ ,  $3.36\pm 0.12$  mm for 7 days;  $4.74\pm 0.15$ ,  $5.43\pm 0.20$ ,  $5.63\pm 0.14$  mm for 28 days and  $6.74\pm 0.05$ ,  $7.09\pm 0.04$ ,  $8.64\pm 0.17$  mm for 112 days old Uttara fowl, respectively (Table 2, Fig. 3). Samte (2008) recorded that the outer diameter (average) of the colon at the proximal, middle and distal portions which was 1.702, 2.124, 2.309 mm

for day-old; 2.55, 2.851, 3.152 mm for 7 days; 4.576, 5.042, 5.611 mm for 28 days and 6.708, 7.046, 8.532 mm for 112-days old Kadaknath fowl respectively. The wall thickness (average) of proximal, middle and distal portions of colorectum was  $0.42\pm 0.05$ ,  $0.69\pm 0.02$ ,  $0.96\pm 0.05$  mm for day old;  $0.89\pm 0.03$ ,  $1.08\pm 0.03$ ,  $1.35\pm 0.08$  mm for 7 days;  $1.28\pm 0.16$ ,  $1.55\pm 0.01$ ,  $1.73\pm 0.05$  mm for 28 days and  $1.75\pm 0.07$ ,  $1.84\pm 0.07$ ,  $1.83\pm 0.03$  mm for 112 days old Uttara fowl, respectively (Table 3, Fig. 4). Samte (2008) recorded wall thickness (average) of the colon at the proximal, middle and distal portions as 0.434, 0.744, 0.889 mm for day old; 0.927, 1.008, 1.172 mm for 7 days; 1.487, 1.548, 1.686 mm for 28 days and 1.746, 1.975, 1.83 mm for 112-days old Kadaknath fowl respectively. The inner diameter (average) of proximal, middle and distal portion of colorectum was  $1.33\pm 0.03$ ,  $1.65\pm 0.01$ ,  $1.21\pm 0.04$  mm for day old;  $1.95\pm 0.02$ ,  $1.81\pm 0.04$ ,  $2.07\pm 0.05$  mm for 7 days;  $3.51\pm 0.09$ ,  $3.82\pm 0.05$ ,  $3.58\pm 0.13$  mm for 28 days and  $4.79\pm 0.06$ ,  $5.29\pm 0.04$ ,  $6.54\pm 0.11$  mm for 112 days old Uttara fowl respectively (Table 4, Fig. 5). Samte (2008) recorded the inner diameter (average) of the colon at the proximal, middle and distal portions of colon as 1.267, 1.380, 1.420 mm for day-old; 1.623, 1.842, 1.980 mm for 7 days; 3.255, 3.494, 3.925 mm for 28 days and 4.960, 5.250, 6.70 mm for 112-days old Kadaknath fowl respectively.

### **Ultra-structural studies**

SEM examination of proximal caecum in day old Uttara fowl bird revealed that villi were uniformly finger shaped (Fig. 6). This corresponds to the shape of duodenal villi in white leghorn as described by Kalita (2009) in Kadaknath fowl. Villi showed a dome shaped tip. Surface was not smooth and showed crevices throughout the surface and horizontal recesses were quite prominent. In distal caecal

portion of day old bird, villi were absent and only mucosal folds with wavy appearance were present. Surface was diffusely corrugated with no distinguishable structure. Many goblet cell pores were present throughout the surface (Fig. 7 and 8).

SEM Studies in colorectum of day old bird revealed that most of the villi were tongue like shape with curved tip. Hexagonal cell outlines were observed on higher magnification. These findings are in accordance with findings of Kalita (2009) in ileum of Kadaknath fowl. SEM studies in proximal caecum of 112 day old bird revealed the growth in size and horizontal recesses disappeared and surface became corrugated with many goblet cell pits. These findings are contrary to findings of Kalita (2009) in duodenum and jejunum who reported plate like villi. Tips of villi from dome shape changed to a tapering peak like shape. On the apical surface epithelial cell clusters were quite prominent. Distal Caecum in 112 day old revealed a rough surface which may be due to the extrusion of epithelial surface imparting a honey comb like structure. Colorectum villi in 112 day old bird increased in size but there were no distinct change in their morphology from day old bird. The villi were tongue shaped with curved tip (Fig. 9).

The present study showed that the large intestine of Uttara fowl comprised of a pair of well-developed caeca starting from ileocolic junction which were blind pouches extending along the line of small intestine towards liver cranially. Colorectum was short tube starting from ileocecolic junction to cloaca. Length of caecum and colorectum increased significantly with increasing age. Length and weight of left caecum was found slightly greater than right caecum in corresponding age groups. Scanning electron microscopy revealed that the villi were finger shaped with the tip as dome shaped in older birds in the

proximal portion of caecum. However, the tip of the villi became tapered later. Goblet pits were found in the distal portion of caecum. The villi were tongue shaped in colorectum and had corrugated surface.

### **Acknowledgement**

The authors are very much grateful to the Dean, CVASc, GBPUAT, Pantnagar and In-Charge, Electron Microscopy Lab, GBPUAT, Pantnagar for providing necessary facilities in carrying out the research work in time. The authors are thankful to the Indian Council of Agricultural Research, New Delhi (ICAR-JRF) for providing the financial assistance.

### **References**

- Argenzio, R. A. 1980. Pathophysiology of diarrhoea. *Veterinary Gastroenterology*. Lea and Febiger publication Ltd., Philadelphia, USA. Pp. 172-198.
- Bayer, R. C., Rittenburg, J. H., Bird, F. H., Chawan, C. B., and Allen, M. 1981. Influence of short term fasting on chicken alimentary canal mucosa. *Poultry Science*. 60: 1293-1302.
- Bradley, O. C. and Grahame, T. 1960. The structure of the fowl. *The Structure of the Fowl*. 4: 31-50.
- Braun, E. J., and Duke, G. E. 1989. Function of the avian cecum. *J. Exp. Zool. Suppl.* (USA). Pp. 16-22.
- Chauhan, R. S. 2003. *Veterinary laboratory diagnosis*. IBDC, Lucknow. Pp.293-297.
- Clench, M. H. 1999. The avian cecum: update and motility review. *J. Exp. Zool.* 283: 441-447.
- Ewa Dziala-Szczepanczyk and Katarzyna Betlejewska 2003. Morphology and morphometry of caeca in the black scoter *Melanitta nigra*. *Electronic*

- Journal of Polish Agricultural Universities. Vol. 6, Issue 2.
- Ewa Dziala- Szczepanczyk. 2006. Morphometric characteristics of the caecum in long tailed ducks *Clangula hyemalis* wintering on the polish Baltic Coast. Electronic Journal of Polish Agricultural Universities. Vol. 9, Issue 12.
- Getty, R. 1975. Sisson and Grossman's the Anatomy of the Domestic Animals, 5th Edition. vol. 2. WB Saunders, Philadelphia, PA.
- Ghosh, R. K. 1995. Primary Veterinary Anatomy. 1st edn. Current Books Internationals, Calcutta. Pp. 115-149.
- Hassouna, E.M.A. 2001. Some anatomical and morphometrical studies on the intestinal tract of chicken, duck, goose, turkey, pigeon, dove, quail, sparrow, heron, jackdaw, hoopoe, kestrel and owl. Assiut Veterinary Medical Journal. 44: 47-78
- Hodges, R. D. 1974. The digestive system. The histology of the fowl. Pp. 35-112.
- Kalita, P.C. 2009. Gross morphometric, Light and electron microscopic studies on the small intestine of the Kadaknath fowl. Doctoral dissertation G.B.P.U.A. & T. Pantnagar- 263145.
- Kaur, N. 2007. Studies on morphological, haemato-biochemical and production traits in local hill fowl of Pithoragarh region. Ph.D. Thesis. G.B.P.U.A&T, Pantnagar.
- Kaur, N., Kumar, S., Singh, B., Pandey, A.K. and Somvanshi, S.P.S. 2010. Morphological characterization of feathered shank local hill fowl of Central Himalayan Region of India. Indian J. Anim. Sci. 80(9): 934-936.
- King, A. S., and McLelland, J. 1975. Soc. Vet. Sci. 65: 607-614.
- Mahmud, M. A., Shaba, P., Shehu, S. A., Danmaigoro, A., Gana, J. and Abdussalam, W. 2015. Gross morphological and Morphometric Studies on Digestive Tracts of Three Nigerian Indigenous Genotypes of Chicken with Special Reference to sexual Dimorphism. J. World's Poult. Res. 5(2): 32-41
- Majeed, M. F., F.S. Al- Asadi, F. S., Al. Nassir, A. N. and Rahi, E. H. 2009. The morphological and histological study of the caecum in broiler chicken. Bas J Vet Res. 8:19-25.
- Malorni, W., Fais, S. and Fiorentini. 1998. Morphological aspects of apoptosis. Apoptosis: laboratory manual of expt. Methods (Andria Cossoriza and Diana Boraschi, Ed.). Pardue University, West Hafayette, USA.
- McLeod, W. M. 1939. Anatomy of the digestive tract of the domestic fowl. Veterinary Medicine. 34: 722-727.
- McNab, J. M. 1973. The avian caeca: a review. Worlds Poult Sci J. 29:251-263.
- Nasrin, M., Siddiqi, M. N. H., Masum, M. A. and Wares, M. A. 2012. Gross and histological studies of digestive tract of broiler chicken during post natal growth and development. J. Bangladesh Agril. Univ. 10(1): 69-77.
- Nickel, R., Schummer, A. and Seiferle, E. 1977. Anatomy of the domestic birds. Verlag Paul Parey.
- Pant, D., Kumar, A., Kumar, S., Kumar, D., Korde, J.P., Singh, B. and Kaur, N. 2007. In National Symposium on poultry production for rural employment and nutritional security" organized by GADVASU, Ludhiana, April 21-23.
- Pilz-Formen, S. Ü. 1937. Die Mikroskopischen Boden-Pilze.
- Romanoff, A. L. 1960. The avian embryo. The avian embryo. Structural and functional development. The avian

- embryo. Structural and functional development.
- Samte, L. 2008. Gross morphometric, Light and electron microscopic studies on the large intestine of Kadaknath fowl. Master's dissertation G.B.P.U.A.&T., Pantnagar.
- Sisson, S. & Grossman, J. D. 1953. The Anatomy of the Domestic Animals. Philadelphia: WB Saunders Company. Pp. 940-941.
- Son, J. H., Karasawa, Y., and Nahm, K. H. 2000. Effect of caecectomy on growth, moisture in excreta, gastrointestinal passage time and uric acid excretion in growing chicks. *Brit. Poultry Sci.* 41(1): 72-74.
- Son, J. H., Ragland, D., and Adeola, O. 2002. Quantification of digesta flow into the caeca. *Brit. Poultry Sci.* 43(2): 322-324.
- Turk, D. E. 1982. The anatomy of the avian digestive tract as related to feed utilization. *Poultry Science.* 61: 1225-1244.
- Ushakumary, S., Geetha Ramesh and Vijayaraghavan, C. 2002. Lymphoid aggregation in caecum and colon of Japanese Quail. *Indian Journal of Veterinary Anatomy.* 14:16-21.
- Verma, D., Malik, M.R., Shrivastava, A. M. and Parmar, M. L. 1998. Morphometry of intestine in pre and post-hatch fowl (*Gallus domesticus*). *Indian J. Vet. Anat.* 10(1&2): 61-69.

**How to cite this article:**

Pandit, K., B.S. Dhote, D. Mahanta, S. Sathapathy, S. Tamilselvan, M. Mrigesh and Mishra, S. 2018. Gross and Ultra-Structural Studies on the Large Intestine of Uttara Fowl. *Int.J.Curr.Microbiol.App.Sci.* 7(03): 1464-1476. doi: <https://doi.org/10.20546/ijcmas.2018.703.175>