

Case Study

<https://doi.org/10.20546/ijcmas.2018.712.102>

## Ocular Myiasis Caused by *Chrysomya bezziana* – A Case Report

T. Anna<sup>1</sup>, D. Anandhi<sup>2</sup> and G. Sucilathangam<sup>3\*</sup>

<sup>1</sup>Department of Veterinary Parasitology, Veterinary College and Research Institute,  
Tirunelveli - 627 001, Tamil Nadu, India

<sup>2</sup>Department of Ophthalmology, Tirunelveli Medical College, Tirunelveli - 627 011,  
Tamil Nadu, India

<sup>3</sup>Department of Microbiology, Government Theni Medical College, Theni - 625 512, Tamil  
Nadu, India

\*Corresponding author

### ABSTRACT

#### Keywords

Ocular myiasis,  
*Chrysomya*  
*bezziana*, Old  
World screwworm,  
Third instar larvae

#### Article Info

Accepted:  
10 November 2018  
Available Online:  
10 December 2018

Myiasis, the tissue invasion of living vertebrate animals by the fly larvae is commonly observed throughout tropical regions of the world. The phenomenon is also witnessed among humans where unhygienic conditions are prevalent. We reported one case of 29 years old female associated with hard palate perforation who had complaints of whitish worm like structure creeping out of her nose and mouth. On examination, Lacrimal fistula noted in lacrimal sac area of right eye in which maggots were found. The larva isolated was that of third instar larvae *Chrysomya bezziana* (Old World screwworm). After removal of all the maggots, the eye was washed with sterile normal saline and the patient was treated with intravenous antibiotics. CT facial bones showing no sign of bone involvement with normal sinus. Ocular myiasis caused by *Chrysomya bezziana* was reported for the first time from Southern part of Tamilnadu. Although ocular myiasis is rare, a high index of clinical suspicion is required and myiasis should be considered a differential diagnosis of loasis.

### Introduction

Myiasis is defined as the invasion of living and/or dead animal tissue by dipterous fly larvae (maggots) and is common throughout the tropics. Occurrence and site of invasion of myiasis vary with the sanitary conditions, environmental factors, and presence of devitalised tissue that results from traumatic injury, erosive, ulcerative or haemorrhagic

lesions (Sivaramasubramanyam and Sadanand, 1968).

Ocular involvement or ophthalmomyiasis is seen to occur in about 5% of all cases of myiasis (Burns, 2012). Larvae, most commonly, attack the external surface of the eyes or ocular adnexa, e.g. the lids, conjunctiva or lacrimal ducts (external ophthalmomyiasis, EOM). In uncommon

instances they may penetrate into the eyeball itself (internal ophthalmomyiasis, IOM) or may involve the orbit (orbital myiasis).

It is unusual to diagnose and manage ocular myiasis. The parasites most commonly affecting the eye and orbit are the larva of *Hypoderma bovis* (hornet fly), *Oestrus ovis* (sheep nasal botfly), and, rarely, by *Chrysomya bezziana*. EOM caused by dipterous fly larvae has been reported from India (Lagacé-Wiens *et al.*, 2008; Sutherst *et al.*, 1989) Most of these cases have been due to *Oestrus ovis*, and a few (mostly of orbital disease) due to *Chrysomya*. We describe one rare case of ocular myiasis associated with hard palate perforation caused by *Chrysomya bezziana* in a tertiary care hospital.

### Case Report

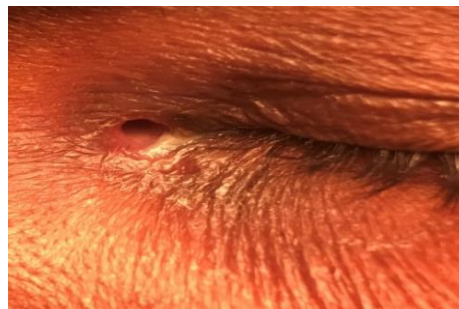A 29 years old female with facial cellulitis from ENT Outpatient Department was referred to Ophthalmology department. She presented to us with no specific complaints. After meticulous history taking from her mother the patient had complaints of whitish worm like structure creeping out of her nose and mouth. The patient persistently denied the above complaint. She had no significant past history. On general examination poor oral hygiene was noted.

On examination her vision is 6/6. Lacrimal fistula noted in lacrimal sac area of right eye in which maggots were found (Figure 1 and

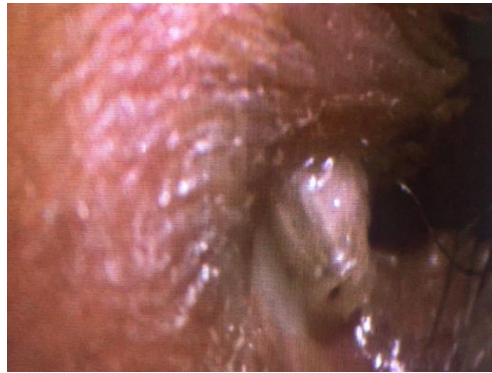
2). Clear Conjunctiva, clear cornea, normal AC depth, pupil 3mm reacting to light were noted. Lens clear. On fundus examination media clear, CDR 0.3, disc and vessels normal, FR present. On other system examination dental malalignment found, halitosis +, large perforation in hard palate were noted. *Ptyriasis versicolor* was noted all over the body.

Freely moving maggots were removed with the help of forceps, under local anaesthesia using 4% xylocaine. Regular dressing of the wound was done, with removal of maggots, for next 4 days. A total of 6 maggots were removed. The maggots were preserved in 10% formalin and sent for entomological evaluation to the Department of Microbiology (Figure 3 and 4). The larvae were identified and confirmed by Parasitology Department of Veterinary College. On direct examination, the larvae were creamy white in colour, with cuticular spines, and varied in size due to different stages of presentation, from 5 to 15 mm. They had strong robust mouth hooks, with four to six papillae on the anterior spiracles, incomplete posterior spiracular peritreme and pigmented dorsal tracheal trunks in the terminal twelfth larval segment. Based upon these findings they were confirmed to be larvae of *C. bezziana* (Figures 5–10). After removal of all the maggots, the eye was washed with sterile normal saline and the patient was treated with intravenous antibiotics.

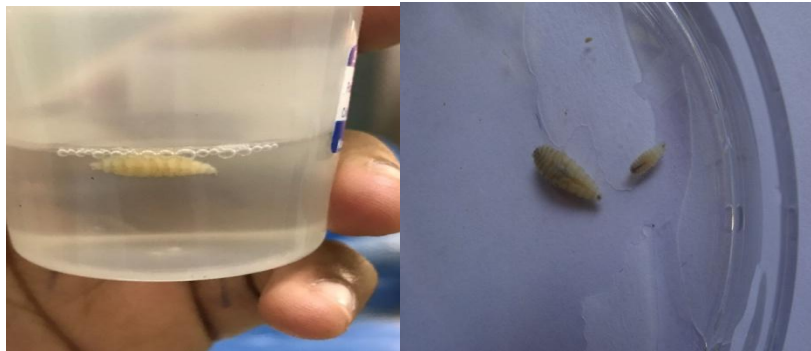**Figure.1** Lacrimal fistula with pus discharge



**Figure.2** Lesion with free-moving maggots




**Figure.3&4** Maggots removed from patient's eye



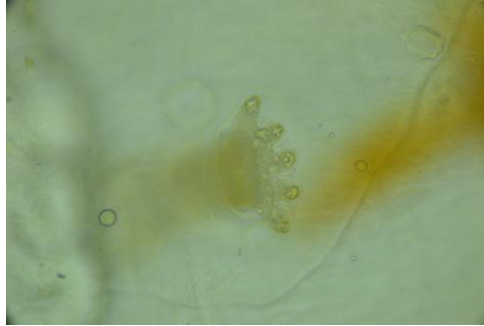
**Figure.5** Anterior end of third stage larva (40x)



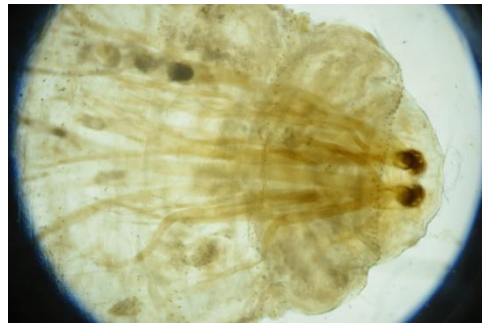**Figure.6** Body spines of Third stage larva (100x)



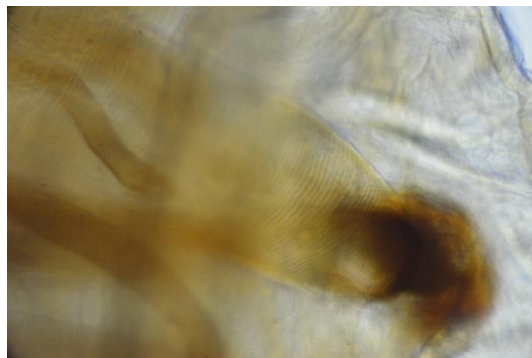
**Figure.7** Anterior spiracles of Third stage larva(40x)



**Figure.8** Posterior end of Third stage larva(40x)



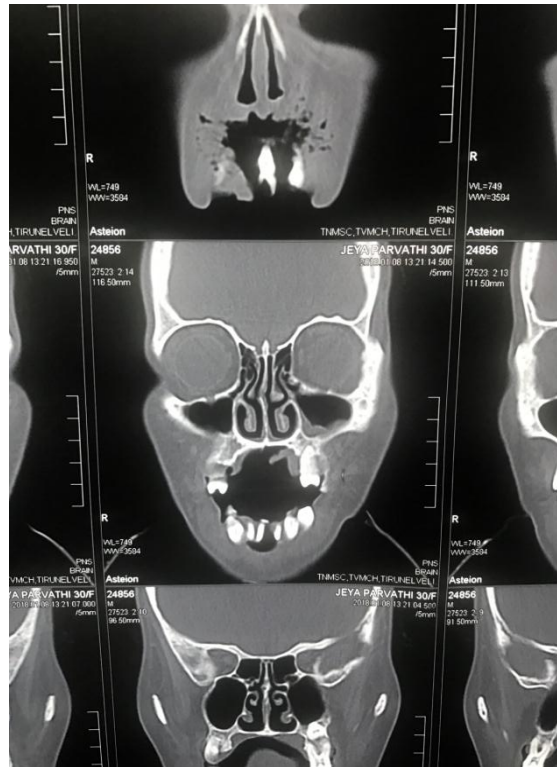
**Figure.9** Dorsal tracheal trunks of Third stage larva(100x)



**Figure.10** Posterior spiracles of Third stage larva(100x)

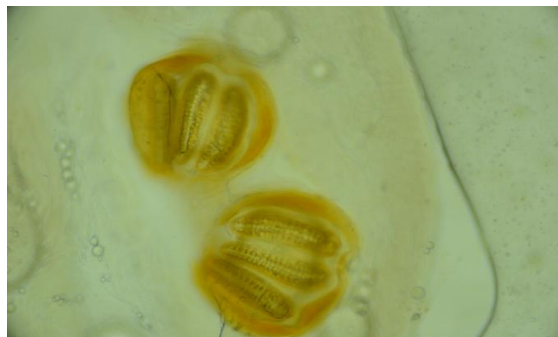

Figure.11 CT facial bones showing no signs of bone involvement, with normal sinuses



CT facial bones showing no sign of bone involvement with normal sinus (Figure-11). The patient was followed up for a further two weeks, and no complication was noted. Dermatology opinion was obtained.

## Discussion

Ocular myiasis is divided into orbital, internal or external, based on site of larval infestation. Larva with invading habits cause orbital and internal ophthalmic manifestation leading to destructive ophthalmic manifestation. External ophthalmic myiasis refers to superficial infestation of ocular tissue including conjunctiva. There are three families which cause ophthalmic infestation i.e., *Oestridae*, *Calliphoridae* and *Sarcophagidae*.

Internal ophthalmic myiasis is blinding disease as compared to external disease. In infestation with larva, browning habits may

lead to severe loss of vision. All these flies are oviparous and eject their eggs on manure and dead tissue leaving them to hatch to larvae (Maggots). They have appearance of white worms with segmentation. In primary ocular myiasis the early form of lesion is in the form of conjunctivitis and corneal ulceration and subsequently penetration to conjunctiva leading to destructive orbital or internal ophthalmic myiasis.

Normally, healthy individuals are unlikely to suffer from myiasis. Chronic debilitating conditions, such as leprosy, diabetes mellitus, open wounds, fungating carcinomas, psychiatric illness, intellectual disability, hemiplegia, and immunosuppressive agents may predispose individuals to myiasis. Infestation with *C. bezziana* differs from usual maggot infestations because it can invade tissue without pre-existing necrotic tissue and cause extensive damage to living

tissue if the condition is left undiagnosed. It buries itself deep in the tissue, causes necrosis, and remains firmly attached to it with help of its cuticular spines. The main predisposing factors for the larval infestation in our patient were probably poverty and poor hygiene.

There are 12 species in the genus *Chrysomya*, most of which are known to cause myiasis in animals. In the literature, only *C. bezziana* and *Cochliomyia hominivorax* have been implicated in causing ophthalmomyiasis in living humans (Khurana *et al.*, 2010). The adult fly of *Chrysomya* is green or blue-green in colour and feeds on decaying matter, excreta, and flowers. Approximately 150–200 eggs at a time are laid by the female adult, on exposed wounds and mucous membranes of the mouth, ears, and nose. After 24 hours, eggs hatch, and larvae burrow deep into the living tissue in a screw like fashion, completing their development while feeding on host tissue for 5–7 days. Thereafter they fall to the ground to pupate. The pupal stage is temperature-dependent, with sexual maturation in approximately 1 week to 2 months. Thus it takes 2–3 months to complete their life cycle (Walker, 1994).

We reported one case of 29 years old female associated with hard palate perforation who had complaints of whitish worm like structure creeping out of her nose and mouth. The larvae were creamish white, 12–18 mm long, worm like gradually tapering at the anterior end. The anterior spiracles were plamate in shape each being composed of 4-6 lobes arranged in a single row located at dorso-posterior margin on each side of prothorax. The posterior spiracles consisted of three oblique slits encircled by dark thick peritreme that is incomplete ventro-medially around the compressed button. The maggots were identified to be third instar larvae of *C.bezziana* on the basis of anterior, posterior

spiracles and cephalopharyngeal apparatus with the help of available keys in literature (Erzinclioglu, 1984; Sukontason *et al.*, 2006).

Various methods for removal of the maggots have been documented. The basic principle involves either suffocating the larvae and forcing them out or first paralyzing them followed with mechanical debridement and Systemic treatment with broad-spectrum antibiotics (Ashenhurst and Pietucha, 2004; Swetter *et al.*, 1996). Successful treatment of myiasis depends upon the stage of presentation, severity, and associated predisposing conditions. In this case, after removal of all the maggots, the eye was washed with sterile normal saline and the patient was treated with intravenous antibiotics. CT facial bones showing no sign of bone involvement with normal sinus (Fig. 11).

Ophthalmomyiasis is an uncommon condition but becomes significant in debilitated and compromised patients. Measures such as general cleanliness of surroundings, maintaining good personal hygiene, provision of basic sanitation, and health education have to be stressed, for preventing myiasis.

In conclusion, successful treatment of myiasis depends upon the stage of presentation, severity, and associated predisposing conditions. The prevention of human myiasis is, therefore, important and involves control of fly population, general cleanliness of dwelling areas and provision for basic sanitation and health education.

### **Acknowledgement**

The authors are gratefully acknowledge The Dean, Tirunelveli Medical College Hospital, Tirunelveli, Tamil Nadu and The Staff of Microbiology, Ophthalmology Department of Tirunelveli Medical College Hospital and

Department of Veterinary Parasitology,  
Veterinary College and Research Institute,  
Tirunelveli.

## References

- Ashenhurst M and Pietucha S.(2004)Management of ophthalmomyiasis externa: case report. *Can J Ophthalmol.* 39(3):285–287.
- Burns, D.A. (2012). Diseases caused by arthropods and other noxious animals. In: Rook's Textbook of Dermatology. Vol. 2. Oxford, UK: Blackwell Science, 11th ed.33.1–33.63.
- Erzinclioglu, Y.Z. (1984). Studies on morphology and Taxonomy of the immature stage of Calliphoridae, with analysis of phylogenetic relationships within the family, and between it and other groups in the Cyclorrhapha (Diptera), Durham thesis, Durham University.
- Khurana, S., Biswal, M., Bhatti, H. (2010) Ophthalmomyiasis: Three cases from North India. *Indian J Med Microbiol.* 28(3):257–261.
- Lagacé-Wiens, P.R., Dookeran, R., Skinner, S., Leicht, R., Colwell, D.D., Galloway, T.D. (2008) Human ophthalmomyiasis interna caused by *Hypoderma tarandi*, Northern Canada. *Emerg Infect Dis.* 14(1): 64–66.
- Sivaramasubramanyam P and Sadanand AV. (1968) Ophthalmomyiasis. *Br. J. Ophthalmol.*, 52(1): 64.
- Sukontason, K.L., Piangjai, S., Boonsriwong, W., Bunchu, N., Ngern-Klun, R., Vogtsberger, R.C. and Sukontason, K. (2006). Observations of the third instar larvae and puparium of *Chrysomya bezziana* (Diptera Calliphoridae). *Parasitology Research* 99: 669-674.
- Sutherst, R.W., Spradbery, J.P., Maywald, G.F. (1989) The potential geographical distribution of the Old World screw-worm fly, *Chrysomya bezziana*. *Med Vet. Entomol.* 3(3): 273–280.
- Swetter, S.M., Stewart, M.I., Smoller, B.R. (1996) Cutaneous myiasis following travel to Belize. *Int J Dermatol.* 35(2): 118–120.
- Walker, A.R. (1994). *The Arthropods of Human and Domestic Animals. A Guide to Preliminary Identification.* London: Chapman & Hall.

### How to cite this article:

Anna, T., D. Anandhi and Sucilathangam, G. 2018. Ocular Myiasis Caused by *Chrysomya bezziana* – A Case Report. *Int.J.Curr.Microbiol.App.Sci.* 7(12): 819-825.  
doi: <https://doi.org/10.20546/ijcmas.2018.712.102>