

Case Study

<https://doi.org/10.20546/ijcmas.2018.712.048>

Surgical Correction of Perosis/Slipped Tendon in a White Pekin Duck- Case Report

Priyanka^{1*}, Satbir Sharma², R.N. Chaudhary³, Ram Niwas³
Neeraj Arora³ and Pooja Yadav³

¹Department of Animal Husbandry & Dairying, Haryana

²Department of Veterinary Clinical Complex, ³Department of Veterinary Surgery & Radiology, Lala Lajpat Rai University of Veterinary and Animal Sciences, Hisar, Haryana, 125004, India

*Corresponding author

ABSTRACT

Keywords

Duck, Perosis, Slipped tendon, Surgical management

Article Info

Accepted:
04 November 2018
Available Online:
10 December 2018

The present case report deals with surgical management of perosis/slipped tendon in a White Pekin Duck reported to Teaching Veterinary Clinical Complex, LUVAS Hisar. Also the present study concluded that perosis can be managed successfully in young ducks. Euthanasia may be necessary if the condition cannot be corrected.

Introduction

Perosis or slipped tendon is luxation of the gastrocnemius tendon forcing the affected leg into a valgus position with an enlarged hock in poultry (Greenacre, 2015). It is caused by deficiency of manganese, choline or biotin. Perosis is caused by manganese deficiency as this mineral is responsible for activation of several and Laursen-jones, 1977). Choline is also needed by ducks, and poor growth and perosis were observed in choline deficient

Pekin ducks (Bernard and Demers, 1949). In chickens and turkeys, dietary choline deficiency caused perosis and a significant decrease in growth rate and feed intake (Ryu *et al.*, 1995). Deformity of hocks, enlargement of condyle, bowing of tarsometatarsus, slipping of gastrocnemius tendon (Shivaprasad, 2002) are some clinical signs of perosis in poultry. Perosis can be prevented by giving appropriate nutritional supply while in chronic cases surgical management is necessary.

Case history and observations

A male white pekin duck was presented to TVCC of LUVAS hisar with the history of lameness, puffiness of both hock joints and non weight bearing since a week. On clinical examination, swelled hock joint (Fig. 1) and displacement of achillies tendon to medial side of the both hock joints (Fig. 2) with shallow trochlea were found.

Treatment and Discussion

The duck was anaesthetised with combination of Xylazine @ 1.0-4.0 mg and ketamine @5.0-30mg/kg intramuscularly (Olsen, 1994). Only right limb was operated. The site was aseptically prepared. Incision was given over caudolateral aspect of the hock joint (Fig. 3) midway between the lateral condyle of the tibio-tarsus and the medially displaced tendon

(Bennett, 1997). Tendon was first freed of adhesions and returned to correct position within trochlear groove. As the trochlear groove was shallow it was deepened and tendon sheath was Sutured to lateral periosteum (Fig. 4b) through a tunnel in the lateral epicondyle produced using a 20 gauge needle by 3-0 absorbable suture in simple interrupted pattern (Olsen, 1994 and coles, 1997) (Fig. 5). Skin incision was Closed in simple interrupted pattern by 4-0 non-absorbable suture (Fig. 6). Leg was bandaged in flexed position and splint applied for approximately one week. Antibiotic cefotaxime @100mg/kg body weight intramuscularly (Ritchie *et al.*, 1994) for 5 days and meloxicam @0.1mg/kg p.o for 3 days (Machin, 2005) was prescribed. Manganese rich diet (rice and chickpeas) was also included in ration of duck.

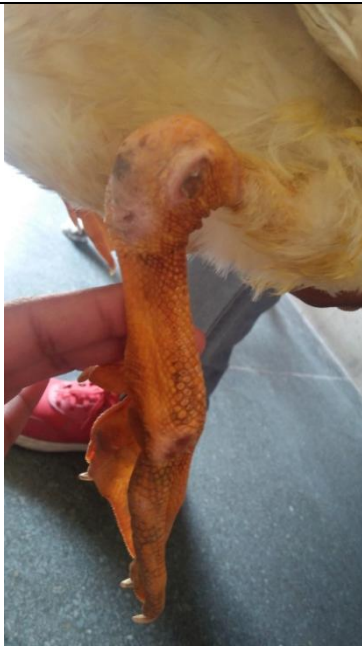

Fig.1 Swelling of right hock joint with skin discolouration

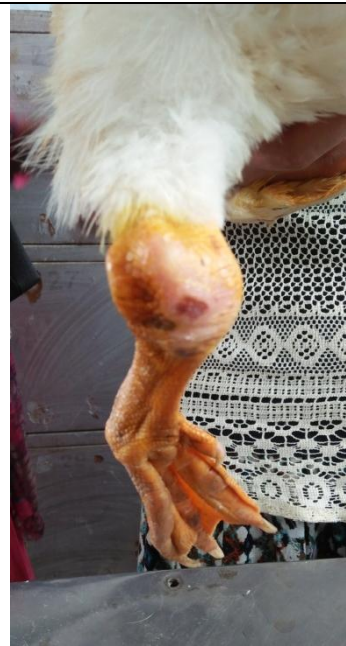


Fig.2 Swelled and dislocated left hock joint, Achilles tendon dislocation on medial side of the joint

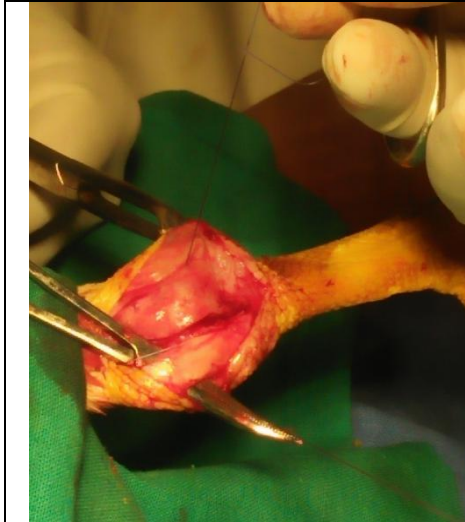


Fig.3 Intra-operative image showing displaced Achilles tendon to medial side.

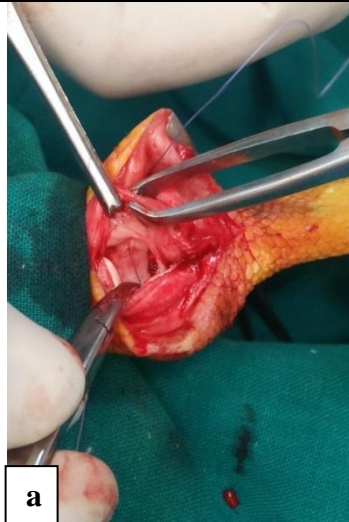

Fig.4 Intra-operative image showing (a) trochlea and (b) suturing of tendon sheath with periosteum of epicondyle.

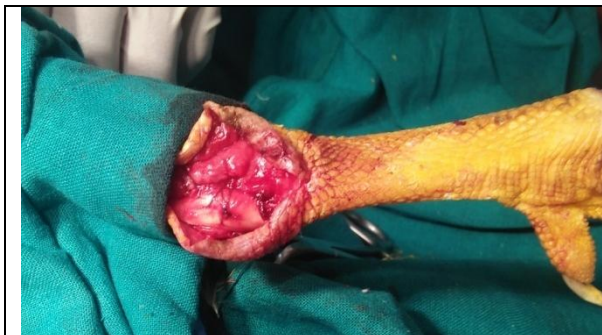

Fig.5 Simple interrupted suture pattern for stacking of tendon sheath to periosteum.

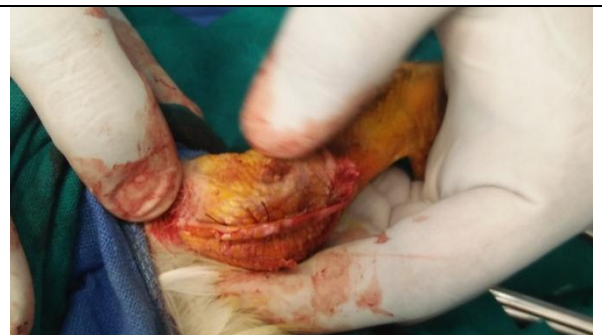

Fig.6 Skin closure with non-absorbable suture material in simple interrupted pattern.

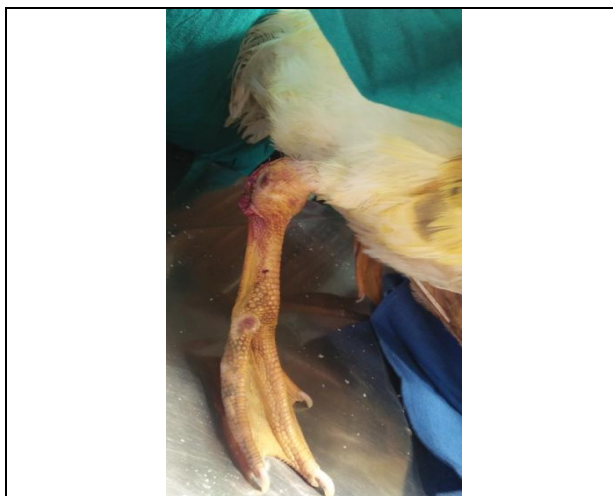

Fig.7 One week post-operative image showing in place Achilles tendon and normalised hock.

One week post-operatively the duck was slightly started bearing weight on affected leg. On clinical examination the tendon was at its normal position (Fig. 7). Suturing or tacking of tendon sheath in place with supplementing the required minerals has variable success. Perosis occurred among the unsupplemented and to a less extent among those receiving the lower level of Mn. So, a diet should contain 40 mg/kg Mn for growth and normal development of ducklings (Van and Pearson, 1955). Perosis caused by choline deficiency could be reduced by increasing dietary choline and was completely prevented when dietary choline was 1182 mg/kg and above (Wen *et al.*, 2014). The results of surgery are better if presented early in clinical sign and in young ducklings (Greenacre, 2015) Ducklings receiving an artificial diet of casein, starch, gelatine, vitamins and minerals except manganese failed to grow, and perosis appeared at from 10 to 15 days of age (Bernard and Demers, 1952). So, from present case it was concluded that perosis can be managed successfully in young ducks. Euthanasia may be necessary if the condition cannot be corrected.

References

- Bennett, R. A. (1997). Orthopedic Surgery. Avian Medicine and Surgery.
- Bernard, R., and Demers, J. M. (1952). Manganese in the nutrition of the White Pekin duckling. *Revue canadienne de biologie*, 11, 147-158.
- Butler, E. J., and Laursen-Jones, A. P. (1977). Nutritional disorders. *Poultry Diseases*, 158.
- Coles, B. H. (1997). Avian Medicine and Surgery. Ed. *Blackwell Science. Second Edition. Pags*, 81(82): 210.
- Greenacre, C. B. (2015). Musculoskeletal diseases. In *Backyard Poultry Medicine and Surgery: A Guide for Veterinary Practitioners* (pp. 145-159). Wiley-Blackwell, Ames, IA.
- Machin, K. L. (2005). Controlling avian pain. *Compendium April*, 299-307.
- Olsen, J. H. (1994). Anseriformes. *Avian Medicine: Principles and Application. Lake Worth, FL: Wingers*, 1263.
- Ritchie, B. W., Harrison, G. J., and Harrison, L. R. (1994). *Avian* (p. 1339). Lake Worth, FL: Wingers publishing.
- Ryu, K. S., Roberson, K. D., Pesti, G. M., and Eitenmiller, R. R. (1995). The folic acid requirements of starting broiler chicks fed diets based on practical ingredients. 1. *Medicine: Principles and Application Interrelationships with dietary choline. Poultry Science*. 74(9): 1447-1455.
- Shivaprasad, H. L. (2002, April). Pathology of birds—an overview. In *CL Davis Foundation Conference on Gross Morbid Anatomy of Animals, AFIP, Washington DC* (pp. 1-48).
- Van Reen, R., and Pearson, P. B. (1955). Manganese deficiency in the duck. *Journal of Nutrition*, 55, 225-234.
- Wen, Z. G., Tang, J., Hou, S. S., Guo, Y. M., Huang, W., and Xie, M. (2014). Choline requirements of white Pekin ducks from hatch to 21 days of age. *Poultry Science*. 93(12): 3091-3096.

How to cite this article:

Priyanka, Satbir Sharma, R.N. Chaudhary, Ram Niwas, Neeraj Arora and Pooja Yadav. 2018. Surgical Correction of Perosis/Slipped Tendon in a White Pekin Duck- Case Report. *Int.J.Curr.Microbiol.App.Sci*. 7(12): 389-392. doi: <https://doi.org/10.20546/ijcmas.2018.712.048>