

Original Research Article

<https://doi.org/10.20546/ijcmas.2018.710.023>

## Gross and Morphometrical Studies on Mandible of Civet Cat (*Viverricula indica*)

Shalini Suri, Jasvinder Singh Sasan\* and Kamal Sarma

Division of Veterinary Anatomy, F.V.Sc & A.H, SKUAST-Jammu, R.S Pura-181102, India

\*Corresponding author

### ABSTRACT

Mandible was the largest bone of the skull. It was a single bone and consisted of two halves that articulated cranially at intermandibular symphysis. The mandible lodged all the lower teeth. The body was concave dorsoventrally and presented three alveoli for incisors and a large alveolus for canine in each half of the mandible. The labial surface was more extensive than lingual surface. The symphyseal surface faced each other and formed intermandibular symphysis. It was rough and irregular. The rami were right and left and were symmetrical. Each ramus was flattened from side to side. The two rami diverge to form a large "V" shaped mandibular space. The horizontal part of rami was of same height from the level of 1<sup>st</sup> to last cheek tooth. The lateral surface of horizontal part presented two distinct mental foramina out of which the cranial mental foramen was located just in front of cheek tooth and was larger as compared to caudal mental foramen. The alveolar border was nearly straight. A wide space, diastema, separated the canine from 1<sup>st</sup> premolar. This border presented alveoli for two premolars and a single molar tooth each with two roots. The posterior border was thick, convex and rounded. It continued posteriorly to form angular process. The vertical ramus was much thinner as compared to horizontal part due to presence of a masseteric fossa on its lateral surface. It was roughly triangular in outline. Medially, the vertical ramus presented mandibular foramen. Both the mandibular and mental foramen was located at about the same level. The articular extremity of vertical ramus presented a non-articular coronoid process and an articular condyle separated by mandibular notch. Coronoid process was flattened from side to side. The condyle was transversely elongated convex articular process that formed temporo-mandibular articulation with squamous temporal bone.

#### Keywords

Angular process,  
Coronoid process,  
Diastema, Mandible,  
Masseteric fossa

#### Article Info

Accepted:  
04 September 2018  
Available Online:  
10 October 2018

### Introduction

The small Indian civet (*Viverricula indica*) is a civet native to South and Southeast Asia. It is listed as Least Concern on the IUCN (International Union for Conservation of Nature and Natural Resources) Red List because of its widespread distribution, widespread habitat use and healthy

populations living in agricultural and secondary landscapes of many range states (Choudhury *et al.*, 2015). Dorsal crest and absence of long black hairs distinguish it from the large civet. It is a smaller animal with a body length of 3 ft, a tail length of 1 ft and weighs 6-8 lbs. the general colour varies from brownish or olive grey to light grey. There are longitudinal dark stripes and rows of spots

along the body. The small Indian civet is a shy animal and almost entirely nocturnal in habit. In literature, abundant information is available on gross anatomy of mandible of domestic animals (Raghavan, 1964). Literature is also available on mandible of domestic cat (Sebestiani and Fishbeck, 2005), camel (Chaurasia *et al.*, 2010), tiger (Tiwari *et al.*, 2011), blackbuck (Choudhary *et al.*, 2015).

Due to paucity of literature on the mandible of small Indian civet, the present study has been planned. The outcome of this study will be useful to the field veterinarians, zoo veterinarians and wildlife experts.

### **Materials and Methods**

The present study was conducted on the mandible of an adult civet cat. The bone was processed as per standard technique (Raghavan, 1964) to record gross morphological features. The various parameters of mandible of civet cat were recorded with help of Vernier Caliper, thread and scale in centimeter. Different parameters studied included (Fig. 1):

Greatest linear length of mandible (A)

Maximum mandibular height (B)

Mandibular foramen to the base of mandible (C)

Cranial mental foramen to the base of mandible (D)

Mandibular foramen to the caudal mandibular margin (E)

Height of coronoid process from condyle (F)

Condyle to base of the mandible (G)

Mandibular foramen from last cheek tooth (H)

Greatest length and width of the mandibular space

Length of diastema

Length of condyle

Distance between caudal mental foramen and caudal mandibular border

Distance between caudal mental foramen and rostral mental foramen

Distance between rostral mental foramen and incisor root

Condyle height index was calculated as per Hoshi (1971)

### **Results and Discussion**

Mandible was the largest bone of the skull as mentioned earlier by Raghavan, (1964) in ox, Chaurasia *et al.*, (2010) in camel and Tiwari *et al.*, (2011) in tiger. It was a single bone and consisted of two halves that articulated cranially at intermandibular symphysis. The mandible lodged all the lower teeth.

It presented a body and two rami as described earlier by Raghavan, (1964) in ox. The body was concave dorsoventrally and presented three alveoli for incisors and a large alveolus for canine in each half of the mandible (Fig. 2). Sebestiani and Fishbeck, (2005) observed three incisors followed by a single sharp canine in domestic cat. Similar observation was made by Kalita *et al.*, (2001) in leopard, Joshi, (2004) in Indian tiger and Lahunta, (2013) in dog. The lingual surface was smooth and concave whereas labial surface was smooth and convex. It was more extensive than lingual surface as observed by Raghavan, (1964) in ox. The symphaseal surface faced each other and formed intermandibular symphysis. It was rough and irregular (Fig. 3).

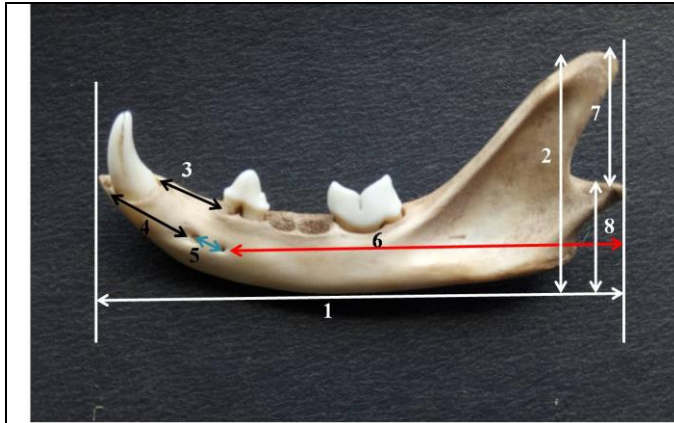
The rami were right and left and were symmetrical. Each ramus was flattened from side to side. The two rami diverge to form a large “V” shaped mandibular space as also observed by Shahid and Kausar (2005) in one-humped camel. Each ramus consisted of two parts namely horizontal part which presented alveoli for cheek teeth (Fig. 2) and vertical part. The horizontal part was of same height from the level of 1<sup>st</sup> to last cheek tooth. The lateral surface of horizontal part presented two distinct mental foramina (Fig. 2). Cranial mental foramen was located just in front of cheek tooth and was larger as compared to caudal mental foramen (Fig. 2). Kalita *et al.*, (2001) also observed two mental foramina in leopard. Sebestiani and Fishbeck, (2005) observed two or three mental foramina in domestic cat. Tiwari *et al.*, (2011) also observed 2-3 mental foramina in mandible of tiger, middle one being the largest. This mental foramen is the external opening of mandibular canal. The alveolar border was nearly straight. A wide space, diastema,

separated the canine from 1<sup>st</sup> premolar (Fig. 2). This border presented alveoli for two premolars and a single molar tooth each with two roots. The posterior border was thick, convex and rounded. It continued posteriorly to form the angular process (Fig. 2) as also observed in domestic cat (Sebestiani and Fishbeck, 2005) and dog (Raghavan, 1964).

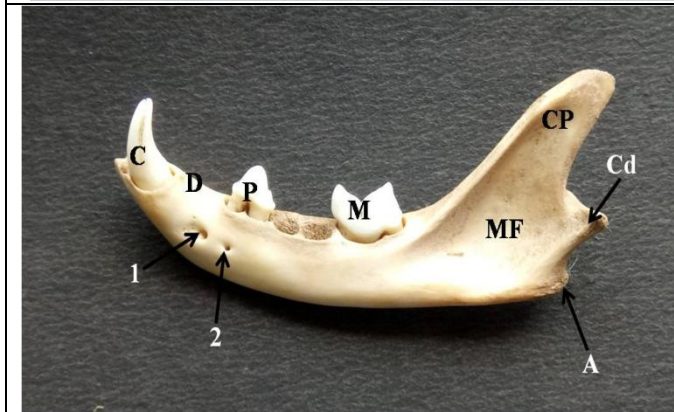
The vertical ramus was much thinner as compared to horizontal part due to presence of a depression on its lateral surface called masseteric fossa (Fig. 2). It was roughly triangular in outline. Similar observations were made by Raghavan, (1964) in dog, Sebestiani and Fishbeck, (2005) in domestic cat and Tiwari *et al.*, (2011) in tiger. In some species such as bear, it is divided into upper and lower parts by a low crest (Hoshi, 1971). Medially, the vertical ramus presented mandibular foramen (Fig. 3) which marked the entrance into the mandibular canal. Both the mandibular and mental foramen were located at about the same level.

**Table.1** Biometrical parameters of mandible of civet cat

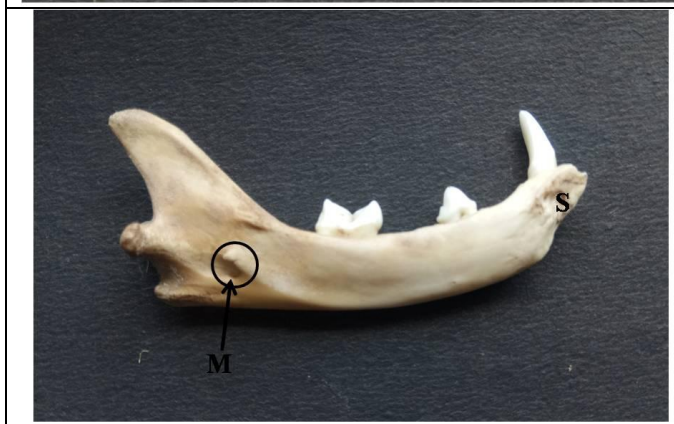S. No.	Parameters	Value (in cm)
1	Greatest linear length of mandible (A)	4.8
2	Maximum mandibular height (B)	2.3
3	Mandibular foramen to the base of mandible (C)	0.4
4	Cranial mental foramen to the base of mandible (D)	0.4
5	Mandibular foramen to the caudal mandibular margin (E)	0.9
6	Height of corocoid process from condyle (F)	1.2
7	Condyle to base of the mandible (G)	0.9
8	Mandibular foramen from last cheek tooth (H)	0.9
9	Greatest length of the mandibular space	4
10	Greatest width of the mandibular space	3.5
11	Length of diastema	0.6
12	Length of condyle	1.2
13	Distance between caudal mental foramen and caudal mandibular border	3.68
14	Distance between caudal mental foramen and rostral mental foramen	0.25
15	Distance between rostral mental foramen and incisor root	0.95
16	Condyle height index	10.69



**Fig.1** Lateral surface of mandible showing measurements: greatest linear length (1), maximum height (2), length of diastema (3), distance between rostral mental foramen and incisor root (4), between rostral and caudal mental foramen (5) between caudal mental foramen and caudal mandibular border (6), height of coronoid process from condyle (7), condyle to the base of the mandible (8)



**Fig.2** Lateral surface of mandible showing rostral (1) & caudal (2) mental foramen, masseteric fossa (MF), coronoid process (CP), condyle (Cd), angular process (A), canine tooth (C), 1<sup>st</sup> premolar (P) and molar tooth (M) and diastema (D)



**Fig.3** Medial surface of mandible showing mandibular foramen (M) and irregular symphyseal border (S)

The articular extremity of vertical ramus presented a non-articular coronoid process and an articular condyle separated by mandibular notch (Fig. 2). Coronoid process was wide below and tapering above. It was triangular in lateral view (Fig. 2). It was flattened from side to side. The condyle was present behind the coronoid process. It was transversely elongated convex articular process that forms temporo-mandibular articulation with squamous temporal bone.

The greatest linear length and maximum height of mandible was 4.8 cm and 2.3 cm, respectively. Monfared, (2013) reported  $8.3 \pm 1.03$  and  $3.7 \pm 0.59$  cm as length and height for the Persian cat's mandible. However, Saber *et al.*, (2016) measured mean mandibular length and height in flat-headed ( $6 \pm 0.58$  and  $2.97 \pm 0.27$  cm) and round-headed ( $4.43 \pm 0.58$  and  $2.17 \pm 0.25$  cm) Australian domestic cat. The mandibular foramen was 0.9 cm from caudal mandibular

border and 0.4 cm from ventral border of the mandible. The mean distance between the mandibular foramen and the caudal border of mandible was  $1.3 \pm 0.4$ ,  $0.9 \pm 0.2$  cm, while distance from the ventral border of mandible was  $0.7 \pm 0.2$ ,  $0.4 \pm 0.1$  cm in flat- and round-headed skulls of domestic cat, respectively (Saber *et al.*, 2016). The condyle height index was 10.69 which was within the range of carnivores (0.95-18.2) (Hoshi, 1971). Other biometric parameters have been depicted in Table 1.

## References

- Chaurasia, S., Tiwari, Y., Pandey, A., Kumar, V. and Malik, M.R. 2010. Biometry of mandible of camel (*Camelus dromedarius*). *Int. J. Mol. Bio.* 1(1): 25-28.
- Choudhary, O.M., Singh, I., Bharti, S.K., Khan, I.M., Sathapathy, S. and Mrigesh, M. 2015. Gross and morphometrical studies on mandible of blackbuck (*Antelope cervicapra*). *Int. J. Morph.* 33(2): 428-432.
- Choudhury, A., Duckworth, J.W., Timmins, R., Chutipong, W., Willcox, D.H.A., Rahman, H., Ghimirey, Y., and Mudappa, D., 2015. "*Viverricula indica*". *IUCN Red List of Threatened Species. Version 2016. 2*. International Union for Conservation of Nature.
- Hoshi, H. 1971. Comparative morphology of the mammalian mandible in relation to food habit. *Okajimas Fol. Anat. Jap.* 48: 333-345.
- Joshi, H. 2004. Gross anatomical studies of the skull of Indian tiger (*Panthera tigris*). Doctoral thesis, Bikaner, College of Veterinary and Animal Science, Rajasthan Agricultural University.
- Kalita, A., Sarma, M. and Sarma, K.K. 2001. Anatomy of the mandible of Indian leopard. *Ind. Vet. J.* 78(12): 1138-40.
- Lahunta, E.D. 2013. *Miller's Anatomy of the dog*. 4<sup>th</sup> edn. Elsevier Saunders, pp: 104-105.
- Monfared, A.L. 2013. Anatomy of the Persian cat's skull and its clinical value during regional anesthesia. *Global Veterinaria* 10 (5): 551- 555.
- Raghavan, D. 1964. *Anatomy of ox*. Indian Council of Agricultural Research, New Delhi, pp: 97-117.
- Saber, A.S., Caceci, T., Gummow, B and Johns, K. 2016. Morphometric studies on the skull of the Australian domestic cat (*F. catus*) and its clinical implications for regional anesthesia. *J. Vet. Anat.* 9(1): 1-24.
- Sebestiani, A.M. and Fishbeck, D.W. 2005. *Mammalian Anatomy: The Cat*. 2<sup>nd</sup> edn. Morton Publishing Company, Colorado, pp: 21-22.
- Shahid, R.U. and Kausar, R. 2005. Comparative gross anatomical studies of the skull of one-humped camel (*Camelus dromedarius*). *Pak. Vet. J.* 25(4): 205-206.
- Tiwari, Y., Taluja, J.S. and Vaish, R. 2011. Biometry of mandible in tiger (*Panthera tigris*). *Annual Review & Research in Biology* 1(1): 14-21.

## How to cite this article:

Shalini Suri, Jasvinder Singh Sasan and Kamal Sarma. 2018. Gross and Morphometrical Studies on Mandible of Civet Cat (*Viverricula indica*). *Int.J.Curr.Microbiol.App.Sci.* 7(10): 229-233. doi: <https://doi.org/10.20546/ijcmas.2018.710.023>