

Original Research Article

<http://dx.doi.org/10.20546/ijcmas.2016.507.085>

Prospective and Retrospective Study of Ovarian Tumors

G.R.Sumanlatha^{1*}, K. Sumalatha², P. Ramanakumari³, G. Saila Bala³ and A. Bhagyalaxmi¹

¹Department of Pathology, Andhra Medical College, Vishakhapatnam,
Andhra Pradesh State, India

²Department of Pathology, Chalmedaanandrao Medical College,
Karimnagar, Telangana State, India

³Department of Pathology, Guntur Medical College, Guntur, Andhrapradesh State, India

*Corresponding author

ABSTRACT

Keywords

Ovarian tumors,
Benign tumors,
Borderline,
Malignant.

Article Info

Accepted:

25 June 2016

Available Online:

10 July 2016

Ovarian neoplasms are the most fascinating tumors in terms of its histogenesis, clinical behavior and malignant potentiality. This study was done in Guntur medical college, Guntur over 5^{1/2} yrs from January 2005 to July 2010. 322 ovarian tumors were diagnosed. The incidence was 4.2% per year, age ranged from 7-80 yrs with the peak in the fourth decade. Benign tumors were 64%, borderline tumors were 1.5% and malignant tumors were 34.5%. Benign tumors were common in the younger age where as the malignant tumors were more common in the elderly. Surface epithelial tumors were 74.8%, germ cell tumors were 16.5%. Common benign ovarian tumor was serous cystadenoma and the common malignant tumor was serous cystadenocarcinoma. Cystic teratomas were common benign tumors of germ cell origin accounting for 10% of the total ovarian tumors. In the first decade the germ cell tumors are 100% malignant. Sex cord stromal tumors were rare. 3.4% of ovarian tumors were metastatic.

Introduction

Ovarian tumors are the most common gynaecological neoplasms and 5th most frequent cause of cancer death (Scully *et al.*, 1998). Frequency of different ovarian tumors is different for western world and Asian countries.

Ovarian neoplasms cannot be detected early in their development due to their vague nonspecific symptoms which can go unrecognized for a period of time and as it is an intra-abdominal organ.

A female's risk at birth of having ovarian tumor sometime in her life is 6.0-7.0%, of having ovarian cancer is almost 1.5% and dying from ovarian cancer is 1.0% (Day *et al.*, 1997).

Materials and Methods

A Retrospective and Prospective study of Ovarian neoplasms was done in the Department of Pathology, Guntur Medical College, Guntur over a period of 5 ½ yrs

(from January 2005 to July 2010). All the cases of ovarian neoplasms registered at Guntur Medical College/ Government General Hospital, Guntur were taken for the study to analyse the age incidence, histologic variants, bilaterality and staging according to WHO and FIGO guidelines. Total number of retrospective cases were 217 (from January 2005 to May 2008) prospective cases were 105 studied during 2 years period (from June 2008 to July 2010).

A total of 7744 gynaecological cases were received for histopathological examination in which 322 cases were recorded as ovarian neoplasms. The type of specimens were Total abdominal hysterectomy (TAH) with Bilateral salpingo-oophorectomy (BSO), TAH with unilateral salpingo-oophorectomy (SO), salpingo-oophorectomy (SO), Cystectomy, enucleation of the cyst, debulking of the tumor. A few cases with omental biopsies were also included in the study. The case details like age, presenting symptoms were recorded. For retrospective cases the paraffin blocks and H&E stained sections from archives are reviewed and the gross features were noted from the registers. For the prospective cases routine grossing was done and representative tissue was submitted for microscopy. The sections were stained with routine haematoxylin and Eosin. Special stains like PAS and reticulin were done wherever necessary.

Results and Discussion

Total of 322 ovarian tumors were diagnosed clinically and histopathologically. The incidence of ovarian tumors among total gynaecological specimens received in the 5^{1/2} years period is 4.2%. The age incidence was 4th decade followed by the 5th and 3rd decades. Benign tumors account for 64%, borderline tumors 1.5% and malignant tumors 34.5% of total ovarian tumors.

Benign tumors were more common in the younger age where as the malignant tumors are more common in the elderly. Serouscystadenoma is the tumor that can occur at any age. Surface epithelial tumors were the common histological type accounting for 74.8% followed by the germ cell tumors 16.5%. Benign (51%) and malignant (23%) surface epithelial tumors form the major group of total ovarian tumors. The most common benign ovarian tumor is the serous cystadenoma and the common malignant tumor is the serous cystadenocarcinoma. Germ cell tumors are the next common tumors after the surface epithelial tumors and more than 75% occur below third decade. Benign cystic teratomas are the common benign tumors of germ cell origin and account for 10% of the total ovarian tumors and more than 50% of the tumors noticed in the first two decades. In the first decade 100% of the germ cell tumors are malignant. Sex cord stromal tumors are the rare ovarian tumors in which fibromas are the common benign tumors and granulosa cell tumor is the commonest malignant sex cord stromal tumor. 3.4% of the ovarian tumors are metastatic.

Most of the tumors were right sided (53.4%) and (39%) are left sided. Bilaterality is observed in 25 cases (7.7%) in which 12 cases were benign, 6 were malignant and 7 were metastatic tumors. One case (0.9%) of sex cord stromal tumor and 1 case (0.9%) of germ cell tumor showed metastatic tumor deposits. Ovarian tumors were staged by WHO criteria. Most of the tumors were in stage I (71%) followed by stage III (25%) and stage II (4%). The prognosis of the tumor was correlated with the histologic type, grade and stage of the tumor.

During the present study a total of 7744 specimens received, of which 322 (4.2%) cases are ovarian tumors (Table-

1). A similar incidence of 3.7% was recorded from eastern (Indian Journal of cancer, July-September 2010) Asian countries and 4.5% in Saudi Arabia (Indian Journal of cancer, July-September 2010) whereas the incidence is more than double in USA, accounting for 10.6% and 11.6% in Canada according to crude incidence rates, age standardized rates (ASR) of ovarian cancer and other uterine adnexal cancers.

A wide age range from 7-80 yrs was recorded in the present study. Peak incidence was noted in the 4th and 5th decade (Table-2). In a study by Kayastha *et al.*, (Pilli *et al.*, 2002) the age group ranged from 18-70 Yrs. The youngest patient recorded in the present study was 7 yrs and the oldest patient was 80yrs of age.

Benign tumors occurred in all age groups and malignant tumors were common in elderly. In the present study serous cystadenoma is the tumor which occurred in all age groups (Table-5) and is comparable with a similar study done by Tavassoli (Ozols *et al.*, 1997). Mature cystic teratoma accounted for half of ovarian neoplasms that appear in the first two decades of life.

Tumors categorized as benign were 64% (206/322), borderline tumors were 1.5% (5/322) and malignant tumors 34.5% (111/322) (Table-6). In a study by Pilli *et al.*, (Auranen *et al.*, 1996) from India 75.2% of ovarian tumors are benign and in another study by Ahmed *et al.*, (Bjorge *et al.*, 1997) only 59.2% are benign. In a study from western countries where 75%-80% of ovarian tumors were benign.

Borderline tumors in the present study were 5(1.5%). But in a study from Sweden⁽⁸⁾ the borderline tumors were recorded as high as 14-15% (Study of ovarian tumors in Nepal Medical College Teaching Hospital by S Kayastha, 2011; Ahmad *et al.*, 2000;

Prabhakar *et al.*, 1989) of primary ovarian neoplasms. They observed that the incidence of borderline tumors was increasing with concomitant decrease in the invasive malignancies (Prabhakar *et al.*, 1989; Jha *et al.*, 2008; Sumaira Yasmin *et al.*, 2008).

In the present study, the malignant ovarian tumors recorded were 111 (34.5%). In a study done by Pilli *et al.*, 24.8% are malignant and Ahmed *et al.*, recorded malignant tumors as 40.8%.

Surface epithelial tumors are the commonest category of all the ovarian tumors. In the present study they constitute 74.8% of total ovarian tumors. In a similar study from India and Pakistan they comprised 70.9% and 63.5% of all ovarian tumors respectively. The incidence is 50-55% of all ovarian tumors in western countries and 46-50% in Japan. This indicates that incidence of surface epithelial tumors varies from region to region.

In the present study, the benign surface epithelial tumors comprised 79.12% (163/206) of total benign ovarian tumors. In a study by R Jha *et al.*, (2008) they accounted for 48.9% of all benign ovarian tumors.

Most serous tumors are benign and in the present study 61.78% (97/157) are benign. In the west 60% of serous tumors are benign. In a study by R Jha *et al.*, 78.9% were benign. Our study is similar to the study of western countries.

Serous cystadenoma is the commonest benign tumor and it comprised 44.66% of (92/206) total benign tumors and it is comparable with the study done by R jha *et al.*, in which 32.6% are serous cystadenomas.

In the current study 2.43% (5/206) are serous cystadenofibromas of total benign tumors.

Mucinous tumors are the common tumors followed by the serous. In the present study they comprised about 21.11% (68/322) of total ovarian tumors and in a study by R Jha *et al.*, 16.8% are mucinous whereas this figure is 25.5% and 25% in other studies.

Mucinous cystadenomas in the present study account for 91.17% (62/68) of the total mucinous tumors and in a study by R Jha *et al.*, 77.8% of mucinous tumors are benign. In west 75% of mucinous tumors are benign.

Other benign tumors in the present study are one case of Brenner and 3 cases of mixed benign surface epithelial tumors.

In the present study a rare case of seromucinous tumor with mural nodule was recorded.

In our present study five cases (1.55%) of mixed tumors were reported. Out of these three were benign (1.45%) and two cases (1.80%) were malignant tumors. These were one case of seromucinous cystadenoma, one case of serous cystadenofibroma, one case of seromucinous tumor with mural nodule, one case of benign Brenner with serous cystadenocarcinoma, one case of seromucinous cystadenocarcinoma.

The borderline tumors recorded in the present study were 1.5% in which 60% were serous and 40% were mucinous. In the western countries incidence of borderline tumors is 10%.

In our study 3 cases were reported as atypical proliferative serous tumors (APSTs), the age of the patients range from 13 to 58 yrs.

In the current study 2 cases were diagnosed

as atypical proliferative mucinous tumors. The age of the patients were 41yrs and 65yrs.

In the present study, out of all malignant tumors the percentage of malignant surface epithelial tumors was 65.8% (73/111). In a study by R Jha *et al.*, it is 69.23% but in the western world 90% are malignant.

The serous tumors were the common (36.3%) malignant tumors. This figure in other studies is 21.42%.

Serous cystadenocarcinomas were the common malignant tumors and they constituted 51.35% (57/111) of all malignant tumors in the present study and they accounted for 46.2% of all ovarian malignancies. In a study by R Jha and in western countries 30% were malignant.

Mucinous cystadenocarcinomas in the present study accounted for (4/68) 5.88% of all mucinous tumors and it is 22.2% in other studies. The other malignant surface epithelial tumors in the current study were endometrioid (8.2%), malignant Brenner (1.36%), Malignant mixed mullerian tumors (4.1%)

In the present study 6 cases (5.4%) were diagnosed as endometrioid adenocarcinoma. In a study by Sumaira *et al.*, (2002) it is 28.5%.

In our study 1 (0.3%) case of malignant Brenner tumor was reported. Malignant Mixed Mullerian Tumors comprised less than 1% of ovarian tumors. There were 300 cases in the literature. The mean age group was 60 yrs. In our study 3 (0.9%) cases were reported as MMT and in which 2 cases were of the age 40yrs and 1 case is at the age of 62yrs. MMT's are aggressive, with a median survival of approximately 1 year. The tumors of Sex-cord stromal types

observed in this study was 4.65% in which 53% were dignosed as benign and 47% were malignant. In a study by R Jha *et al.*, sex cord stromal tumors are 3% of all ovarian tumors which is less in comparision with the present study. In the benign category, the most commonly observed tumor is fibroma which is 40% of all sex cord stromal tumors and 6.6% each of fibro-thecoma and thecoma. Under the malignant tumors, all were granulosa cell tumors, which constituted 2.17% (7/322) of all ovarian tumors. They accounted for 0.62% of all ovarian tumors in a study by R Jha *et al.* In the present study 4 cases (57%) of adult granulosa celltumor and 3 cases (43%) of Juvenile granulosa tumors were dignosed.

Adult granulosa cell tumors are the low grade malignant tumors and they constitute (4/322) 1.2% of all ovarian tumors. In the present study they occurred in age group of 45yrs (2 cases), 60 yrs (1case) and in 30 yrs (1case). All the tumor, in the current study are unilateral.

3 cases of Juvenile granulosa cell tumors were diagnosed, the age ranged from 12 to 18yrs.

The incidence of germ cell tumors in the present study was 16.5% (53/322) of all ovarian tumors which correlates with a similar study from Asian countries⁷ where it is observed as 11%-16.8% but the incidence of germ cell tumors was observed as high as 30% of all ovarian tumors in western countries.

The majority of germ cell tumors in the present study were mature cystic teratomas, constituting 62.26% of all germ cell tumors. In a similar study 95.58% of germcell tumors were benign. In the current study 1 case of mature cystic teratoma with mucinous cystadenoma was reported. Malignant germ cell tumors in the present

study were 18.01% of all malignant tumors. In a study by R Jha and Karki 11.5% are malignant. The common malignant germ cell tumors in the present study were Dysgerminoma (40%), Mixed germ cell tumors(35%), Yolksac tumor(10%), Immature teratoma, teratocarcinoma, Teratoma with malignant transformation (5%).

Dysgerminoma is an uncommon tumor accounting for 1-2% of primary ovarian neoplasms and 3-5% of ovarian malignancies. The tumor can occur at any age from 7 months to 70 yrs. In our study 1 case of dysgerminoma occurred at the age of 7yrs. Grossly, dysgerminoma is usually unilateral more often in the right ovary which is involved in approximately 50% of cases. In the current study 75% are present in the right ovary which correlates with the literature.

Microscopically dysgerminoma composed of aggregates, islands or strands of large uniform cells surrounded by varying amounts of connective tissue stroma containing lymphocytes. The cells are large, contain oval to round nuclei and ample amount of pale, slightly granular eosinophilic or clear cytoplasm.

Mixed germ cell tumors are composed of more than one neoplastic germ cell element such as dysgerminoma combined with teratoma, yolksac tumor, choriocarcinoma, embryonal carcinoma or polyembryoma..

Immature teratomas are composed of tissues derived from the three germ cell layersand in contrast to the much more common mature teratoma, they contain immature or embryonal structures.

Teratoma with malignant transformation is an uncommon complication of mature cystic teratoma. It occurs in approximately 2% of

cases. The age in the literature ranges from 10 to 88 yrs. In the present study the age of the patient is 45yrs. In the present study one case (0.9%) was reported as Teratocarcinoma.

Yolksac tumor is being diagnosed with much greater frequency nowadays and is the second most common malignant ovarian germ cell neoplasm after dysgerminoma. Grossly yolksac tumors are unilateral, it has the predilection to the right ovary. In our study 2 cases are diagnosed as yolksac tumors which are right sided. The tumor size ranges from 10-12cm, which is round to oval, globular, smooth gray yellow to reddish brown areas because of haemorrhage, with solid and cystic areas on cut section.

Microscopically, it exhibits a wide range of histologic patterns predominantly microcystic, endodermal sinus, glandular, macrocystic patterns and myxomatous pattern. The cells have large, slightly vesicular nuclei, prominent nucleoli and show mitotic activity. The surrounding

capsular sinusoid space is lined by single layer of cells with prominent hyperchromatic nuclei. The eosinophilic, hyaline droplets may be present either within the tumor cells or outside them, they may be numerous and prominent in some tumors.

In the present study 2 cases (0.62%) were diagnosed as leiomyomas.

The ovary is a common site of metastases from other primary malignant tumors. The most common primary origins are the breast, colon and stomach. In the present study 3.42% (11/322) were diagnosed as metastatic. In a study by R jha *et al.*, they accounted for 2.4% of all ovarian tumors.

In a study in Korean population the incidence of metastatic ovarian malignancies account for 13.6% of all ovarian malignancies, which is higher than that in Europe and North America. Out of all metastatic tumors 7(63.63%) cases were bilateral. In the current study 63.63% metastatic tumors were bilateral.

Table.1 Age Incidence of Ovarian Tumors

Year	0-10	11-20	21-30	31-40	41-50	51-60	61-70	71-80	Total
2005	1	7	8	15	12	11	3	-	57
2006	-	11	9	18	10	12	2	-	62
2007	1	6	21	17	22	9	4	1	81
2008	-	1	5	12	19	12	4	2	55
2009	-	5	10	9	8	3	2	-	37
July 2010	-	2	5	9	8	5	-	1	30
Total	2 (0.62%)	32 (9.94%)	58 (18.01%)	80 (24.84%)	79 (24.53%)	52 (16.15%)	15 (4.66%)	4 (1.24%)	322 (100%)

In the present study the maximum number of ovarian tumors were seen in the age group of 31-50 years and constitute almost 49.37% of total tumors.

Fig.1 Histological types of Ovarian Tumors/year

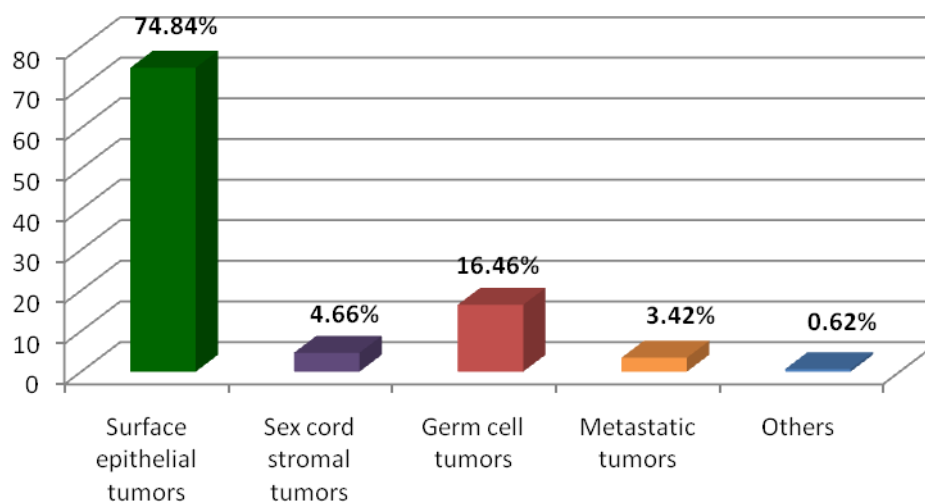


Table.2 Age incidence of Benign Ovarian Tumors

Histologic type	< 10	11-20	21-30	31-40	41-50	51-60	61-70	71-80	Total
Serous cystadenoma		6	21	27	21	11	3	3	92(44.66%)
Mucinous cystadenoma		6	9	19	16	9	3		62(30.09%)
Serous cystadenofibroma			1	1	2	1			5(2.42%)
Benign Brenner				1					1(0.48%)
Mixed surface epithelial tumor		1		1	1				3(1.45%)
Thecoma					1				1(0.48%)
Fibroma		1		2	2	1			6(2.92%)
Fibro-thecoma							1		1(0.48%)
Dermoid cyst		6	17	5	5				33(16.01%)
Leiomyoma				1		1			2(0.97%)
Total	-	20 (9.70%)	48 (23.30%)	57 (27.6%)	48 (23.3%)	23 (11.1%)	7 (3.3%)	3 (1.4%)	206 (100%)

The incidence of the benign tumors was more common in the 4th decade

Table.3 Age incidence of Malignant Tumors

Histologic type	0-10	11-20	21-30	31-40	41-50	51-60	61-70	71-80	Total
Serous cystadenocarcinoma	-	-	-	12	20	21	3	1	57
Mucinous cystadenocarcinoma			1	2	1				4
Endometrioid adenocarcinoma				1		3	2		6
Malignant Brenner					1				1
Malignant Mixed surface epithelial					2				2
MMMT				2			1		3
Dysgerminoma	1	3	3	1					8
Mixed germ cell	1	3	3						7
Yolk sac		2							2
Teratocarcinoma				1					1
Teratoma with malignant transformation					1				1
Immature Teratoma			1						1
Adult granulosa			1		2	1			4
Juvenile granulosa		3							3
Krukenberg			1	3	1	1	1		7
Adenocarcinoma deposit				1	1	2			4
Total	2	11	10	23	29	28	7	1	111

Malignant tumors were more common in the 5th and 6th decade in the present study.

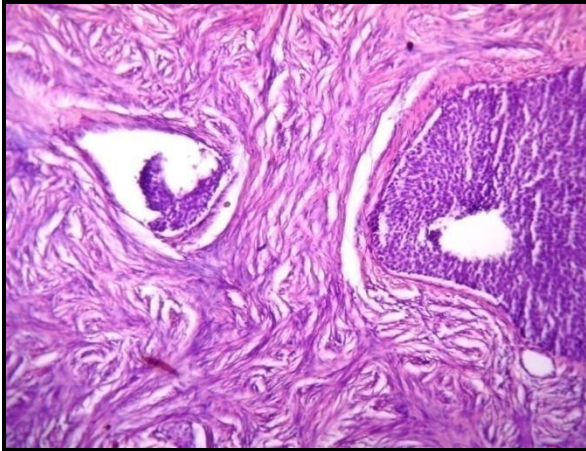


Figure.2 Brenner Tumor

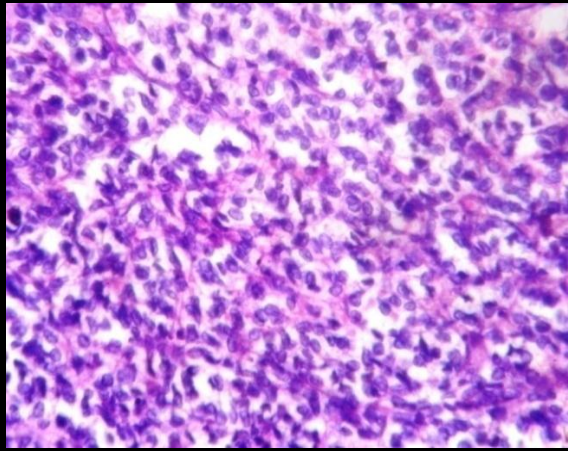


Figure.3 Adult Granulosa Cell Tumor

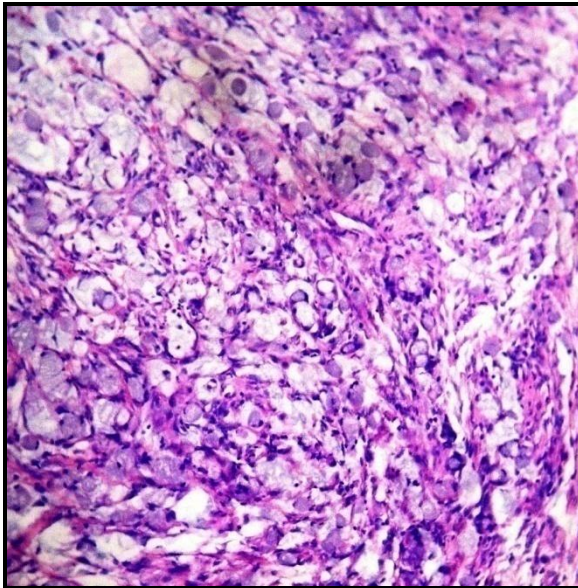


Figure.4 Krukenberg Tumor

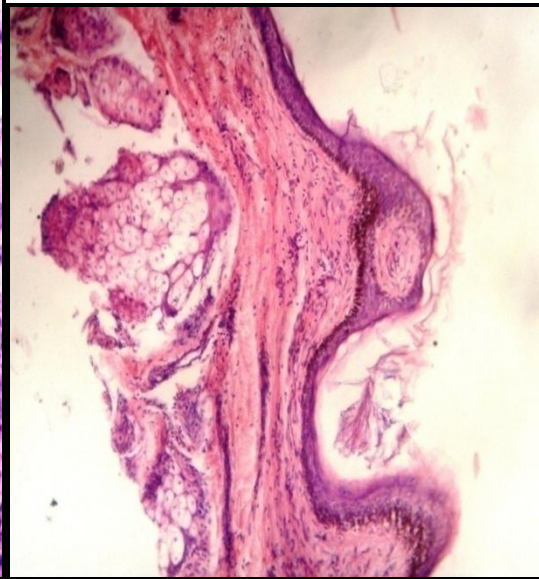


Figure.5 Mature Cystic Teratoma

Total of 11 cases, Krukenberg tumors were 63.63% (7/11) adenocarcinomas were 36.37% (4/11). In these metastatic tumors primary was detected in only 2 cases and in the rest of the 9 cases primary was unknown.

In our study bilaterality was observed in 17 cases of surface epithelial tumors, and 1 case of mixed ovarian tumor i.e teratoma and mucinous cystadenoma and in 7 metastatic tumors.

In the present study tumor deposit is shown most commonly in the omentum, peritoneum, tube, other ovary and other sites. The tumor deposit is shown mostly by the surface epithelial tumors.

Staging of the ovarian tumors was the most important criteria for the prognosis of the individual. In the present study all the ovarian tumors were staged with the parameters like capsular breach, tumor deposit in the other ovary, tube, peritoneum,

omentum, ascitic fluid etc. Most of the tumors in the present study were in stage I (71%), followed by the stage III (25%) and in stage II only few (4%) cases were seen.

References

- Ahmad, Z., Kayani, N., Hasan, S.H. *et al.* 2000. Histological pattern of ovarian neoplasm. *J. Pak. Med. Assoc.*, 500: 416-9.
- Auranen, A., Grenman, S., Makinen, J., Pukkala, E., Salmi, T. 1996. Borderline ovarian tumors in Finland :epidemiology and familial occurrence. *Am. J. Epidemiol.*, 144: 548- 53.
- Bjorge, T., Engeland, A., Hansen, S., Trope, C.G. 1997. Trends in incidence of ovarian cancer and borderline tumors in Norway, 1954-1993, *Int. J. Cancer*, 71: 780-6.
- Clinico histological pattern of ovarian tumors in Peshawar region by Sumaira Yasmin, Aiman Yasmin, Mohammad Asif from *J. Ayub. Med. Coll. Abdoottabad*, 20(4).
- Day, N.E., Krishnan, E. Epidemiology of gynaecological cancers. *Gynaecology by Shaw R W.* 2nd ed. Edinburgh: Churchill Living Stone, p 477-87.
- Idelson, M.G. Malignancy in Brenner tumors of the ovary, with comments on histogenesis and possible estrogen production. *Obstet. Gynecol. Surg.* Indian J. cancer/July-September 2010 /volume 47/ Issue 3.
- Ozols, R.F., Rubin, S.C., Thomas, G., Robboy, S. 1997. Epithelial ovarian cancer, in: Hoskins WJ, Perez CA, Young RC, eds. Principles and practice of gynecologic oncology, 2nd edn. Philadelphia, PA: Lippincott- Raven, 919-86.
- Pilli, G.S., Suneeta, K.P., Dhaded, A.V., Yenni, V.V. 2002. Ovarian tumors: a study of 282 cases, *J. Indian Med. Assoc.*, 100(420): 423-4.
- Prabhakar, B.R., Maingi, K. 1989. Ovarian tumours- prevalence in Punjab. *Indian J. Pathol. Microbiol.*, 32: 276-81.
- Jha, R., S. Karki. 2008. Study on Histological pattern of ovarian tumors and their age distribution. *Nepal Med. Coll. J.*, 10(2): 81-85.
- Scully, Robert, E., Young, Robert, H., Clement, Philip, B. 1998. Atlas of tumor pathology. Tumors of the ovary, maldeveloped gonads, fallopian tube and broad ligament. 3 Murad A. Ovulation induction and ovarian tumors: the debate continues. *J. Pak. Med. Assoc.*, 48: 353-6.
- Skirnisdottir, I., Garmo, H., Holmberg, L. 2007. Non –genital tract metastases to the Ovaries presented as ovarian tumors in Sweden 1990-2003: occurrence, origin and survival compared to ovarian cancer. *Gynecol. Oncol.*, 105: 166-71.
- Study of ovarian tumors in Nepal Medical College Teaching Hospital by S Kayastha. *Nepal Med. Coll. J.*, 11(3): 200-202.
- Tavassoli, F.A., Devilee, P. 2003. WHO classification of Tumors. Pathology and Genetics, Tumors of Breast and Female Genital Organs. IARC Pres: Lyon.
- Young, R.H., Scully, R.E. 2002. Metastatic tumors of the ovary .In: Kurman RJ, editor. Blaustein's pathology of the female genital tract. 5th ed New York: Springer; pp.1063-1101.

How to cite this article:

Sumanlatha, G.R., K. Sumalatha, P. Ramanakumari, G. Saila Bala and Bhagyalaxmi, A. 2016. Prospective and Retrospective Study of Ovarian Tumors. *Int.J.Curr.Microbiol.App.Sci.* 5(7): 741-750. doi: <http://dx.doi.org/10.20546/ijcmas.2016.507.085>