

Original Research Article

<https://doi.org/10.20546/ijcmas.2022.1109.015>

## Effect of Carbon tetrachloride on Liver enzymes and Lipid Peroxidation in Rat

M. Neogy Ganguli, Rabindra Nath Hansda<sup>id\*</sup>, S. Mondal, S. Pradhan and S. K. Mukhopadhyay

Department of Veterinary Pathology, Faculty of Veterinary and Animal Sciences, West Bengal  
University of Animal and Fishery Sciences, Kolkata-700037, India

*\*Corresponding author*

### Keywords

Carbon tetrachloride, albino rat, liver, xenobiotics

### Article Info

**Received:**  
05 August 2022  
**Accepted:**  
29 August 2022  
**Available Online:**  
10 September 2022

### ABSTRACT

In this present study, 12(twelve) albino rats divided into two groups. Each group consisting of three males and three females. T<sup>1</sup> for control group received only liquid paraffin @ 3ml/kg.b.wt. on alternate day for four injections. T<sup>2</sup> group treated with carbon tetrachloride @ 1ml/kg.b.wt. following dilution with liquid paraffin at the ratio of 1: 2 i.e. 3ml/kg.b.wt. subcutaneously on alternate day for four injections. T<sup>2</sup> group rats showed decreased reduced glutathione(5%), increased lipid peroxidation(60%) and decreased SGOT(62.4%). The pathological changes in the liver tissue showed fully changes, coagulative necrosis, cirrhosis and hyperplasia of bile duct.

### Introduction

Liver plays a major role in optimizing nutrient utilization in the body and it is the chief organ for detoxification of a plethora of xenobiotics to which the body is exposed to from time to time. As such hepatic tissue is most vulnerable to the damaging effects of various toxicants including drugs. A variety of drugs undergo extensive hepatic metabolism after administration. Among them some drug candidates such as paracetamol produce extensive hepatotoxic effect when taken on a chronic basis. Hepatoprotective agents from synthetic semisynthetic and natural sources are extensively used to restore the normal function of the liver. Carbon tetrachloride which is widely used

as a potent hepatotoxicant in experimental pharmacology is biotransformed by the cytochrome P-450 system to produce the trichloromethyl free radical, which in turn covalently binds to cell membranes and organelles to elicit lipid peroxidation, disturb Ca<sup>+2</sup> homeostasis and finally results in death of hepatocytes<sup>1</sup>. Here we have studied the effects of carbon tetrachloride on the hepatic enzymes and oxidative damage induced by it in the context of the agent induced pathology of the hepatic tissue.

### Materials and Methods

In this experiment, 12(twelve) albino rats of 7-9 weeks age of either sex were used. Their body

weight varied from 150-250grams. The rats were put into galvanized cages in temperature controlled ( $22\pm 3^{\circ}\text{C}$ ) experimental room seven days before the commencement of the experiment for acclimatization. The animals were fed with standard rat pellets and were provided with water *ad libitum* and kept in a disinfected area.

Rats were divided into two (2) groups, each consisting of three males and three females.  $T^1$  was considered as control, while  $T^2$  was considered as the test group. The animals of  $T^2$  group were treated with carbon tetrachloride at a dose of 1 ml/ kg.b.wt. following dilution with liquid paraffin at the ratio of 1:2(i.e. 3ml of the final mixture injected) subcutaneously on alternate day for a total duration of eight days. The animals of  $T^1$  group were treated with liquid paraffin at a dose of 3ml/kg.b.wt on alternate day for four injections and served as control. At the end of the dosing period rats of both control( $T^1$ ) and test( $T^2$ ) were euthanized and livers were collected for histopathological studies and estimation of biochemical parameters.

For histopathological study, liver was cut into small pieces and placed in 10% neutral buffered formalin. After the subsequent wash and dehydration in ascending grades of alcohol the tissues were embedded in melted paraffin and blocks were prepared. The tissue sections were cut at 3 to 5 micron in digital microtome and stained with haematoxylin and eosin (Luna, 1968) (H& E). Sections were viewed under light microscope at 10X magnification.

The other part of the hepatic tissue was minced with stainless steel blade, washed in chilled distilled water and excess of water was blotted. Liver tissue homogenate (10%) was prepared with chilled distilled water by using tissue homogenizer. The tissue homogenate was further divided into two parts. One part was used for estimation of various hepatic enzymes. For this the required amount of distilled water was added to the tissue homogenate in the ratio of 1:1, so that the final concentration of homogenate was 5%. It was then centrifuged in

refrigerated centrifuge ( $4^{\circ}\text{C}$ ) at 6000 rpm for 20 min. The supernatant was utilized for estimation of liver enzymes like serum glutamic oxaloacetic transaminase (SGOT/AST) and serum glutamic pyruvic transaminase (SGPT/APT). These were estimated spectrophotometrically using different commercial kits (Crest Biosystems, Goa) as per manufacturer's protocol. The other portion of the homogenate was used for estimation of antioxidant enzymes like reduced glutathione and also for determination of lipid peroxidation in the tissue. The reduced glutathione was estimated by the method described earlier by Griffith *et al.*, in 1980 with slight modification. Briefly, 0.1 ml of supernatant of tissue homogenate was mixed with 0.9 ml of tris hydrochloric acid buffer and to it 2 ml of 0.6 mM DTNB was added to make the final volume 3 ml. The reference cuvette contained 0.1 ml of 5% trichloroacetic acid (TCA) in place of tissue sample since it was homogenized in TCA medium. Absorbance was read at 412 nm wavelength. Reduced glutathione content of the tissue was estimated from the standard curve.

Extent of lipid peroxidation in a tissue that serves as an index for oxidative damage was estimated by standard method. Briefly, the supernatant fraction (2 ml) of tissue homogenate (10%) in TCA was mixed with equal volume of 0.67%(w/v) thiobarbituric acid was incubated in boiling water bath for 10 min. The sample was cooled by placing in ice bath for 5 min and then the absorbance was read at 532nm in spectrophotometer.

Then the concentration of malonaldehyde was calculated and expressed as n mole of malonaldehyde/gm of wet tissue. Reduced glutathione was measured in spectrophotometer at 412nm wavelength (Griffith, 1980). Total aliquot of 3ml contained 2 ml of 0.60mM DTNB in 0.20M Tris HCl buffer, pH 8.0. The reference cuvette contained 0.10 ml of 5% trichloroacetic acid instead of the sample and after 5 min absorbance was read at 412 nm wavelength in spectrophotometer. The results were expressed as Mean $\pm$ S.E.M. One way ANOVA was used to find out the significant

difference in between the mean values of different groups of rats.

### Results and Discussion

The enzymatic activities showed that reduced glutathione of liver tissues were decreased significantly ( $p < 0.05$ ) and lipid peroxidation was increased significantly ( $p < 0.05$ ) in T<sup>2</sup> due to hepatic damage made by CCL4. The glutamic oxaloacetic transaminase and glutamic pyruvic transaminase were decreased in liver tissues significantly ( $p < 0.05$ ) in T<sup>2</sup> group as compared to control(T<sup>1</sup>) group.

The pathological changes in the liver of rat treated with carbon tetrachloride showed fatty changes, coagulative necrosis, cirrhosis and hyperplasia of bile duct. Carbon tetrachloride caused decreased and increased of reduced glutathione and lipid peroxidation levels by 5% and 60% respectively. The value of SGOT activity of liver tissue of T<sup>2</sup> group showed 62.4% decreased from the control values. Carbon tetrachloride is one of the most commonly used chemicals to induce hepatotoxicity in experimental study of liver diseases<sup>3</sup>. The

hepatotoxic effect of carbon tetrachloride are mainly due to its active metabolite, trichloromethyl radical (Johnston and Kroensig, 1998; Srivastava *et al.*, 1994). These activated radicals bind covalently to the macromolecules and induce peroxidative degradation of lipid membrane of endoplasmic reticulum rich in polyunsaturated fatty acids.

This leads to the formation of lipid peroxides which in turn generate products like malonaldehyde that cause damage to the lipid membrane. This peroxidative degradation of biomembranes is one of the principal causes of hepatotoxicity of carbon tetrachloride (Griffith, 1980; Kaplowitz *et al.*, 1986).

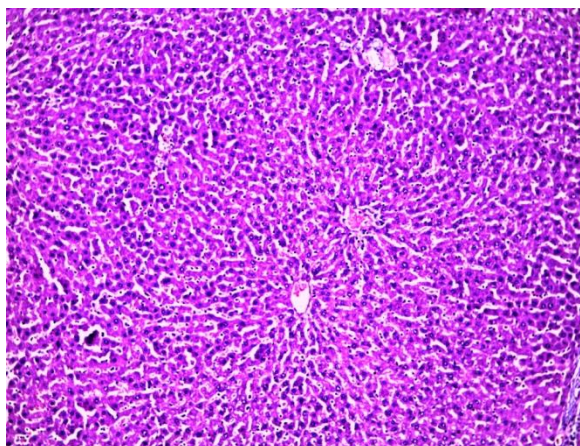
The histopathological lesions of liver reported in this study, closely supports the earlier reports in rats (Achilya *et al.*, 2003; Venukumar and Latha, 2002; Junnila *et al.*, 2000). The observation of the present study regarding significant ( $p < 0.05$ ) decrease in the level of reduced glutathione content of liver tissue of rat is in agreement with previous report (Weber *et al.*, 1982).

**Table.1** Effect of Carbon tetrachloride on different biochemical parameters in liver of rats (n=6, mean ± S.E.).

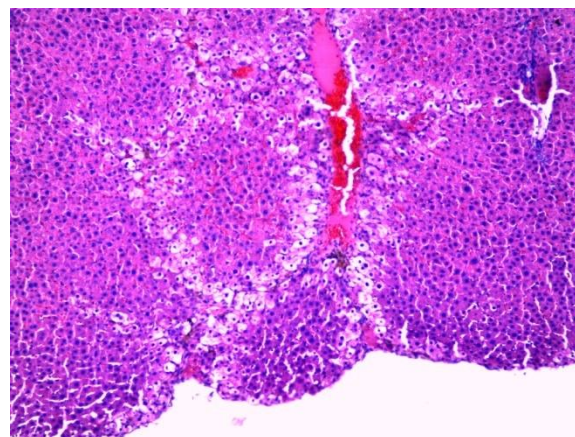
Parameter	Control groups T <sup>1</sup>	Experimental groups T <sup>2</sup> (treated with Carbon tetrachloride)
Reduced glutathione (mM/gm wet tissue)	3.48 ± 0.20	1.90 ± 0.22 <sup>*</sup>
Lipid peroxidation (n mol malonaldehyde/gm wet tissue)	3.70 ± 0.32 <sup>a</sup>	5.92 ± 0.47 <sup>*</sup>
SGOT (µg pyruvic acid/mg/protein/h)	1.98 ± 0.23 <sup>a</sup>	0.74 ± 0.03 <sup>*</sup>
SGPT (µg pyruvic acid/mg/protein/h)	2.05 ± 0.40 <sup>a</sup>	0.80 ± 0.16 <sup>*</sup>

Values are expressed as Mean ± SEM. Values were considered to be statistically significant (\*) when  $P < 0.05$

**Fig.1**



Liver tissue of control (T<sup>1</sup>) rat showing normal architecture (10X)



Liver tissue of experimental group (T<sup>2</sup>) rat showing fatty changes, cloudy swelling (10X)

These strengthens the possibility of oxidative pathology behind carbon tetrachloride induced hepatotoxicity. Thus it can be concluded that carbon tetrachloride which is one of the most commonly used hepatotoxicant in experimental pharmacology induces peroxidative degradation of biomembranes and also alters the level of antioxidants in the hepatic tissue which can be looked upon as the probable mechanism underpinning the mechanism behind its hepatotoxic effect.

### Acknowledgements

The authors are thankful to the Honble. Vice Chancellor, West Bengal University of Animal and Fishery Sciences, Kolkata for providing necessary facilities to carry out this experimental work.

### References

- Achilya, G. S., Kotagale, N. R., Wadodkar, S. G. and Dorle, A. K. (2003). Hepatoprotective activity of panchagavya Ghrita against carbon tetrachloride – induced hepatotoxicity in rats. *Indian Journal of Pharmacology*, 35: 308-334.
- Griffith, O. W. (1980). Determination of glutathione and glutathione disulfide using glutathione reductase and 2-vinylpyridine. *Analytical Biochemistry* 106: 207-212
- Johnston, D. E. and Kroensig C. 1998. Mechanism of

early carbon tetrachloride toxicity in cultured rat hepatocytes. *Journal of Pharmacology and Toxicology*, 83: 231-239.

- Junnila, M., Rakho, T., Sukura, A and Lindberg, L. A. (2000). Reduction of carbon tetrachloride induced hepatotoxic effects by oral administration of betaine in male hanwistar rats. A morphometric histological study. *Journal of Veterinary Pathology*, 37: 231-238.
- Kaplowitz, N., Aw, T. Y., Simon, F. R. and Stolz, A. (1986). Drug induced hepatotoxicity. *Annals of Internal Medicine*, 104: 826-839.
- Luna, L. G.(1968). *Manual of Histologic Staining Methods of Armed forces Institute of Pathology* 3<sup>rd</sup> edition Mac Grew Hill Book Company., New York.
- Srivastava, S., Srivastava, A. K., Srivastava, S., Patnaik, G. K. and Dhawan, B. N. (1994). Effect of picroliv and Silymarin on liver regeneration in rats. *Indian Journal of Pharmacology*, 26: 19-22.
- Venukumar, M. R. and Latha, M. S. (2002). Hepatoprotective effect on the Methanolic extract of curculigo orchoides in carbon tetrachloride treated male rats. *Indian Journal of Pharmacology*, 34: 269-275.
- Weber H U, Fleming J F and Miquel J. (1982). N-acetyl thiazolidine-4-carboxylic acid, a physiologic sulfhydryl anti-oxidant with potential value in geriatric medicine. *Archives of Gerontology and Geriatrics*, 1: 299-310.

**How to cite this article:**

Neogy Ganguli, M., Rabindra Nath Hansda, S. Mondal, S. Pradhan and Mukhopadhyay, S. K. 2022. Effect of Carbon tetrachloride on Liver enzymes and Lipid Peroxidation in Rat. *Int.J.Curr.Microbiol.App.Sci.* 11(09): 131-135. doi: <https://doi.org/10.20546/ijemas.2022.1109.015>