

Original Research Article

<https://doi.org/10.20546/ijcmas.2021.1003.179>

## Prenatal Development in the Sternum and Ribs of Nellore Sheep (*Ovis aries*)

Supriya Botlagunta<sup>1\*</sup>, R. Dhyana<sup>1</sup>, Deepa Pathipati<sup>2</sup> and P. Jagapathi Ramayya<sup>1</sup>

<sup>1</sup>Department of Veterinary Anatomy, <sup>2</sup>Department of embryo biotechnology, Sri Venkateswara Veterinary University, College of Veterinary Science, Tirupati -517502, India

\*Corresponding author

### ABSTRACT

The present investigation included the chronological sequence of appearance of ossification centers and their individual development in the sternum and development of ribs in Nellore sheep fetuses. The development of individual sternebra from 78-139 days of gestation was analyzed. Forty eight apparently healthy Nellore sheep fetuses irrespective of sex were used for this study. The modified double staining for bone and cartilage, radiography and histological staining procedures were used to study the sternebrae of different age groups. Each sternebra ossified from two centers except the first, which has single ossification centre. In most specimens seventh sternebra appeared first at 58 days, followed by third, fourth, fifth, second and then first sternebrae between 60-63 days of estimated age. The Sixth sternebra was the last one to appear at 69 days. In most cases right center of sixth sternebra ossified first than the left one. The relative growth in length (L) and breadth (B) of the seven sternebra (S1, S2, S3, S4, S5, S6, and S7) among the prenatal growth periods of 78-97 days (group I), 98-117 days (Group II) and 118-137 days (Group III) was significant ( $p < 0.05$ ). The relative increase in the length of all the sternebra was more in Group I followed by Group III except in the length of fourth sternebra, which showed more growth during prenatal age of 98-117 days (Group II). In the present study first twelve pairs of ribs were ossified by the estimated age 45 days and the thirteenth pair was ossified at 46<sup>th</sup> day.

#### Keywords

Sheep fetus,  
Prenatal  
ossification,  
Sternum  
development, Ribs  
development

#### Article Info

Accepted:  
12 February 2021  
Available Online:  
10 March 2021

### Introduction

Sternum consisted of unpaired, segmental series of bones which are joined by synchondroses (Konig and Liebich, 2004). In embryological development, two longitudinal cartilaginous bands develop in the ventral

body wall following fusion, endochondral ossification centers gives rise to individual sternebra with in this primordium (Mc Geady, 2006). The ribs in human fetus develop from costal processes which outgrow from the primitive vertebral mass and extend down in the cleft between the myotomes (Arey, 1965)

Chronological sequence of appearance of ossification centres in sternum has been studied in sheep (Wenham, 1981; Majeed, 2008) and other domestic animals (Latshaw, 1987) but information is meagre regarding the development of ribs and the individual development of the each sternebra. Hence, the present study has been undertaken with the aim to investigate the prenatal developmental process in the ribs of the Nellore sheep and the development of individual sternebra from 78-139 days of gestation and its morphometric analysis.

### **Materials and Methods**

A total of forty eight fetuses were collected from uteri of the pregnant ewes slaughtered in and around Tirupati. The crown rump lengths of these fetuses were measured with measuring tape. This length used in Richardson's formula (Arthur *et al.*, 1989) to find the estimated age of each fetus. The age of the fetuses ranged between 40-137 days. The sternum of smaller fetuses having crown rump length between 3.5 and 14cm were prepared by skinning and fixing in absolute ethyl alcohol for 10 days and in acetone for 3 days and then stained with alcian blue and alizarin red (Farzane Sadeghi., 2014).

The stained sternebra were examined to detect the primary ossification centers. The sternum of the fetuses size more than 14 cm crown-rump length were used for radiographs at exposure factors 65 kVp and 10 mAs and 60 kVp and 12 mAs. Some specimens were macerated in diluted solution of potassium hydroxide 2-10% for about 6-24 hours for digestion of muscles. Fetuses less than 3.5cm crown rump length were fixed in 10% neutral buffered formalin and Bouin's fixative and processed for serial paraffin sections of 5-6  $\mu$  and stained with hematoxylin and eosin (Humason, 1962).The growth of bones was studied by using the vernier calipers to

measure the length and breadth of each bone. The fetuses were divided into three groups, group I (78-97 days), group II (98-117 days) and group III (118-137days). Analysis of variance applied on these measurements to detect significant differences in the average of the relative increase of these measurements among studied groups.

### **Results and Discussion**

#### **Sternum**

In sheep two strands of cartilaginous precursor of sternum was identified first at 45<sup>th</sup> day (Fig. 1). Subsequently they underwent endochondral type of ossification. Each sternebrae ossified from two centers except the first. In the present study, manubrium was found to be ossified from single centre as reported earlier (Getty, 1975). The number of sternebra in the sternum of Nellore sheep was seven but in the present study one variant with six sternebra was found (Fig. 2, 133 DAYS). In one specimen seven segments of normal size and one small bone was observed which might be the result of failure of fusion of two ossification centres or additional ossification centre for the sixth sternebra. In sheep first sternebra was cylindrical, second and seventh were triangular, third one was quadrilateral, fourth, fifth and sixth were rectangular in shape (Fig. 2).

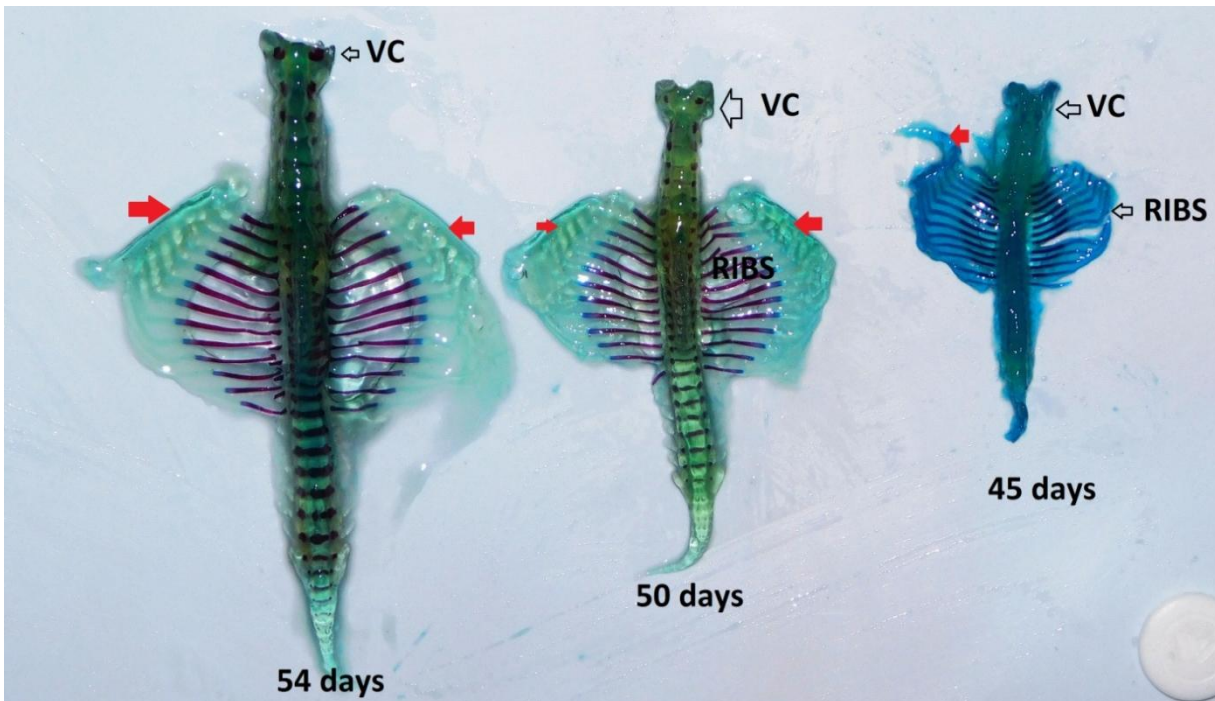
The seventh sternebra was the first to ossify first at 58<sup>th</sup> day. Lindsay (1969) reported that ossification commenced by 75 days of prenatal life in bovine and 60 days onwards in sheep foetus (Wenham, 1981). The ossification of seventh followed by third, fourth, fifth ossified at 62 days, second and then first sternebrae between 63-65 days. The Sixth sternebra was the last one to appear at 69 days of estimated gestation (Fig. 2, 69 DAYS). Fusion of the two centers of sixth sternebra was inconstant.

**Table.1** The length and breadth of the seven sternbrae during the estimated gestational age from 78 to 137 days in Nellore sheep foetus

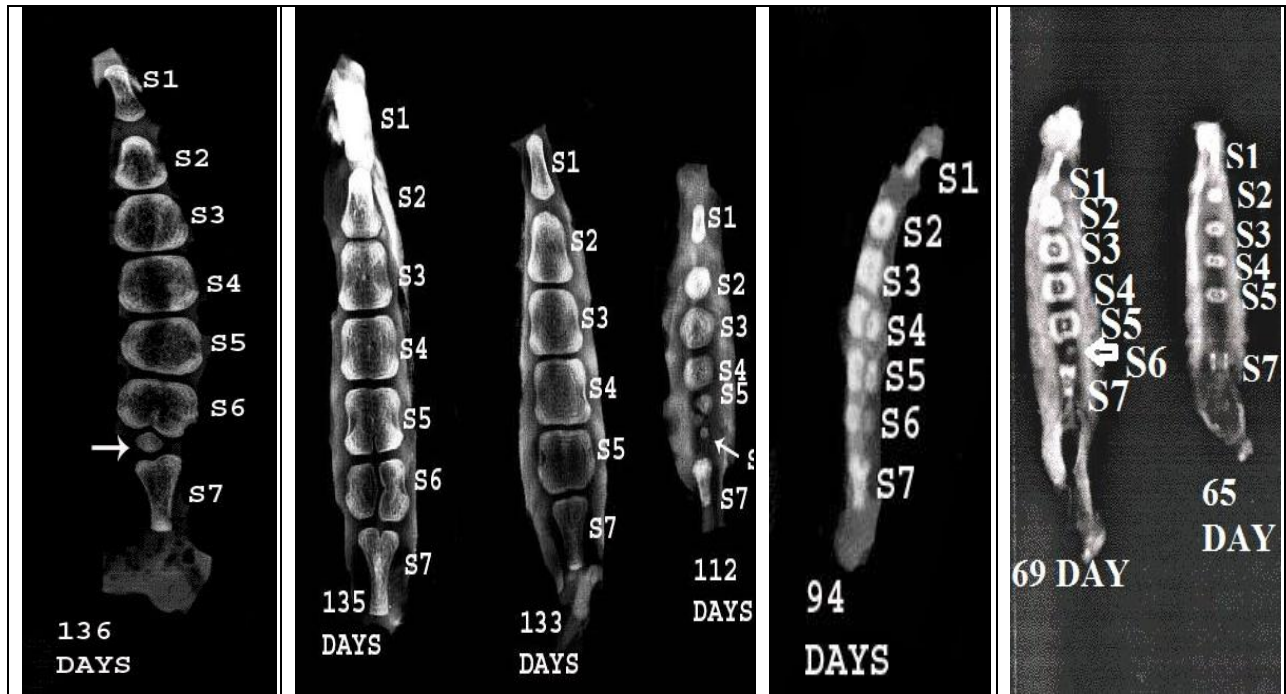
parameter	Group I (78-97 days)	Group II (98-117 days)	Group III (118-137days)
Length of first sternebra (cm)*	0.63±0.04	0.93±0.04	1.43±0.05
Length of second sternebra (cm)*	0.59±0.04	0.89±0.04	1.24±0.02
Breadth of second sternebra (cm)*	0.57±0.03	0.84±0.13	1.14±0.03
Length of third sternebra(cm)*	0.62±0.04	0.96±0.05	1.23±0.02
Breadth of third sternebra (cm)*	0.71±0.05	0.94±0.04	1.27±0.05
Length of fourth sternebra (cm)*	0.63±0.03	0.95±0.12	1.29±0.01
Breadth of fourth sternebra (cm)*	0.80±0.05	1.01±0.05	1.43±0.08
Length of fifth sternebra (cm)*	0.57±0.03	0.81±0.03	1.26±0.01
Breadth of fifth sternebra (cm)*	0.80±0.05	1.11±0.03	1.39±0.10
Length of sixth sternebra (cm)*	0.52±0.03	0.67±0.03	1.26±0.10
Breadth of sixth sternebra (cm)*	0.70±0.06	1.04±0.04	1.53±0.11
Length of seventh sternebra (cm)*	0.76±0.04	0.90±0.12	1.64±0.08
Breadth of seventh sternebra (cm)*	0.54±0.04	0.84±0.12	0.99±0.03

\* Significant with  $p < 0.05$ , values are shown in mean  $\pm$  S.E.

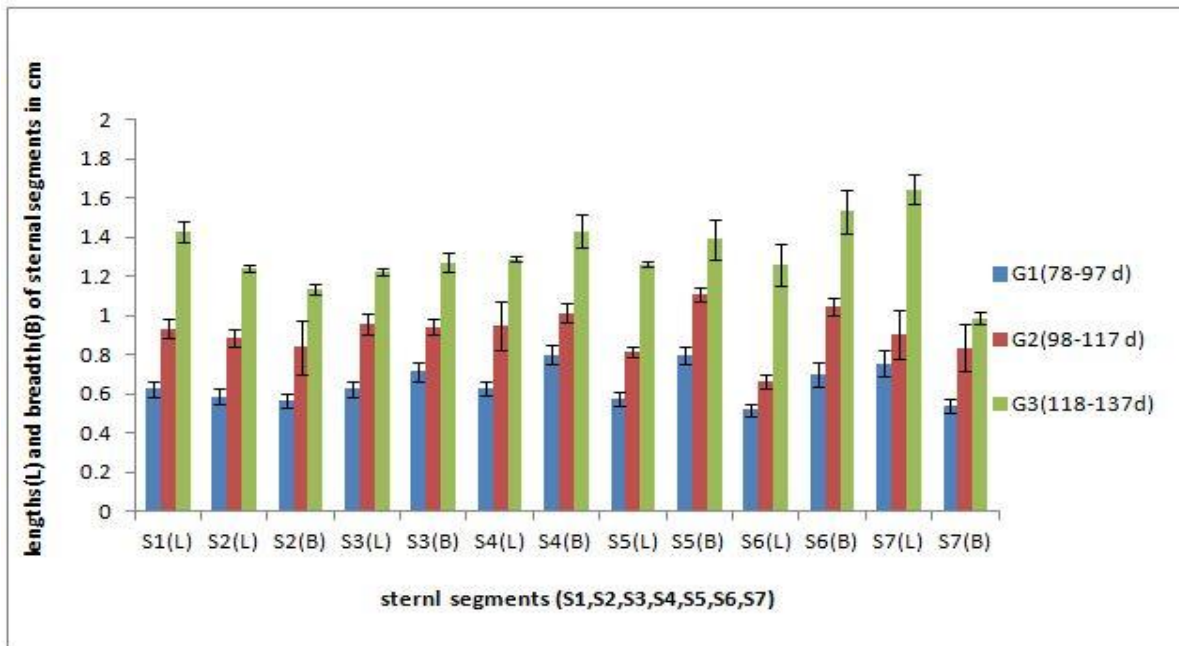
**Fig.1** photograph showing the vertebra column (VC), Ribs and the strands of cartilaginous precursor of sternum (Red arrow) from the Nellore sheep fetuses of estimated gestational age 45 days, 50 days and 54 days. Alizarin red and alcian blue stain for bone (dark pink to red) and cartilage (blue).



**Fig.2** The dorsoventral and oblique radiographs of the sternum showing the seven sternebrae (S1, S2, S3, S4, S5, S6, S7) during the estimated prenatal growth period of 65 day, 69 day, 94 day, 112 day, 133 day, 135 day and 136 day in Nellore sheep fetus.

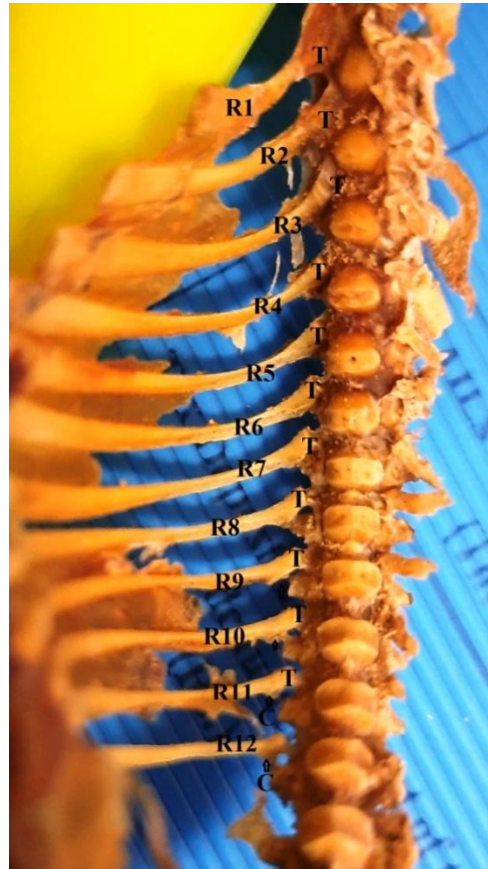

**Fig.3** Bar graph showing the relative increase in length (L) and breadth (B) of the seven sternebra (S1, S2, S3, S4, S5, S6, S7) during the prenatal growth period of 78-97 days (group I), 98-117 days (Group II) and 118-137 days (Group III).





**Fig.4** photograph showing macerated specimen of 94 day sheep fetus having twelve pairs of ribs (R1-R12) with head (C) and tubercule (T).



They were not fused till 135 days in two specimens (Fig. 2, 135 DAYS). The cartilage present behind the 7th sternal segment transformed into xiphoid cartilage in sheep foetus. These reports were in congruent with the reports of Majeed (2008) in Awasi sheep foetus.

He stated that ossification centres in the sternum of Asawi sheep begins in the seventh sternebra at 56 days old, then in the third, fourth, fifth sternebra at 57-59 days old, then in the second, first sternebra at 60-61 days old, while the double ossification centers of the sixth sternebra appeared at 69-71 days of gestation. The minor variation in the days of ossification may be due to variation of the breed under study. Wenham (1981) observed the ossification of sternebrae in sheep foetus

in caudo-cranial sequence. The relative growth in length (L) and breadth (B) of the seven sternebra (S1, S2, S3, S4, S5, S6, and S7) in all the studied groups i.e. group I (78-97 days), group II (98-117 days) and group III (118-137days) was significant ( $p < 0.05$ ) (Table 1). The relative increase in the length of all the sternebra was more in Group I followed by Group III except in the length of fourth sternebra.

The relative increase in length of the fourth sternebra was more in Group II following to that of Group I. The relative increase in the breadth of S2, S3, S4 and S6 was more in Group I followed by Group III. The relative increase in the breadth of S5 and S7 was more in Group I followed by Group II (Fig. 3). According to Majeed, (2008) development in

sternal length was more in the 7th week of fetal age in Awasi sheep, then in the 8th week, then in the 10<sup>th</sup> week.

### Ribs

In sheep thirteen pairs of ribs were present. In our study one variant with twelve pairs was recorded (Fig. 4). In each rib three separate ossification centres were observed, one each for the shaft, head and tubercular facet. The shafts of the first twelve pairs of ribs were ossified by the estimated age 45 days and that of thirteenth pair was ossified at forty sixth day. Where as Wenham (1981) observed ossification in first twelve pairs of ribs from 50 days onwards and Harris (1937) reported ossification in first eleven pairs of ribs at 41 days and rib thirteenth at 43 days of gestation in sheep foetus. Ossification proceeds laterally and ventrally (Fig. 1). Whereas their distal ends remain cartilaginous as reported by Mc Geady *et al.*, (2006). The cartilaginous portion of the rib which did not ossify persists as costal cartilage in all domestic animals.

Secondary ossification centres were observed in heads and tubercular facets of first 12 pairs of ribs at 92 days. According to Getty (1975), the ribs ossified from 3 centres one each for the body, head and tubercle, however, the 3rd centre was absent in some of the caudal ribs.

The results of the present study showed the prenatal development of sternum and ribs in Nellore sheep. The knowledge from the study was brought to bear on how and when during embryogenesis the malformations might occur.

### References

Arey, L B. 1965. the skeletal system. Developmental Anatomy. 7<sup>th</sup> Edition. W.B. Sanders `company, Philadelphia. pp: 405-423.

Arthur, G.H., Noakes, D.E. and Pearson, H. 1989. Veterinary Reproduction and Obstetrics. 6<sup>th</sup> Edn., Bailliere Tindall, London.

Farzane Sadeghi. 2014. Two separated protocols with the most important comments for skeletal staining in embryonic and adulthood period in laboratory animals. Anatomical Sciences. 11: 87-92.

Getty, R. 1975. Sisson and Grossman's The Anatomy of the Domestic Animals. Vol. 1, W.B. Saunders Co., Philadelphia.

Harris, H.A. 1937. Foetal growth of the sheep. Journal of Anatomy 71: 516-527.

Humason, G.L. 1962. Animal Tissue Techniques. W.H. Freeman and Co., Sanfrancisco.

Konig, H.E. and Liebich, H.G. 2004. Text Book and Color Atlas of Veterinary Anatomy of Domestic Mammals, (Eds.) H.E. Konig and H.G. Liebich. Schattauer Publisher, Stuttgart, New York., pp: 197-217.

Latshaw, W.K. 1987. Veterinary Developmental Anatomy. B.C. Decker Inc., Pennsylvania.

Lindsay, F.E.F. 1969. Observations on the loci of ossification in the prenatal and neonatal bovine skeleton. British Veterinary Journal 125: 422-428.

Majeed, N. A. Z. 2008. The embryonic development of the sternum in sheep and goats. *Al-Qadisiyah Journal of Veterinary Medicine Sciences*, 7(2), 50-57.

McGeady, T.A., Quinn, P.J., Fitz Patrick, E.S. and Ryan, M.T. 2006. Veterinary Embryology. Blackwell Publishing Ltd., U.K.

Soliman, M.K. 1975. Studies on the physiological chemistry of the allantoic and amniotic fluids of buffaloes at the various periods of the

pregnancy. Indian Veterinary Journal  
52: 106-112.  
Wenham, G. 1981. Radiographic study of

early skeletal development in fetal  
sheep. Journal of Agricultural Sciences  
96: 39-43.

**How to cite this article:**

Supriya Botlagunta, R. Dhyana, Deepa Pathipati and Jagapathi Ramayya, P. 2021. Prenatal Development in the Sternum and Ribs of Nellore Sheep (*Ovis aries*). *Int.J.Curr.Microbiol.App.Sci.* 10(03): 1463-1469.  
doi: <https://doi.org/10.20546/ijemas.2021.1003.179>